Cardiology Diagnostics – Radiographs, Echo, and Biomarkers

John E Rush, DVM, DACVECC, DACVIM (Cardiology)
Cummings School of Veterinary Medicine at Tufts University, North Grafton, MA, USA

Introduction

Respiratory and cardiac abnormalities are common in dogs and cats, and identification of the specific underlying cause is important for treatment success. Shortness of breath, cough and other respiratory signs may develop from many causes, and the diagnosis is often established based on the results of history, physical examination, laboratory testing (including NT-proBNP and cardiac troponins), thoracic radiographs, ECG and echocardiography. The most valuable tests for establishing a diagnosis of congestive heart failure are thoracic radiographs, echocardiography, and natriuretic peptide testing (NT-proBNP).

Thoracic Radiographs

Cardiac Sze

The experienced clinician often uses subjective assessments of cardiac size for evaluation of the heart. This works well in many dogs and cat, but the subjective assessments have some limitations. While several "Rules of thumb" exist, much of the current literature has emphasized the role of the Vertebral Heart Size (or Scale or Score), abbreviated VHS, which can be used to quantify cardiac size. Measurement of the cardiac silhouette using the VHS indexes the cardiac size to the vertebral length. Using this technique, most dogs have a VHS on the lateral view of 9.5v and the vast majority of dogs with a VHS above 10.5v have significant cardiomegaly. It also appears that a VHS > 11.5v is associated with the development of CHF in the near future. This technique is especially helpful in dogs with a deep chest conformation (i.e., Doberman pinscher or Irish setter) and in those with a wide or barrel shaped chest (i.e., bulldog, pug, and miniature schnauzer). For the lateral radiographic projection in cats, most cats with normal cardiac size with have a VHS less than 8.0v, and many cats with cardiomegaly have a lateral VHS > 8.5v. On the DV view, the short axis VHS measure is usually less than 3.6v.

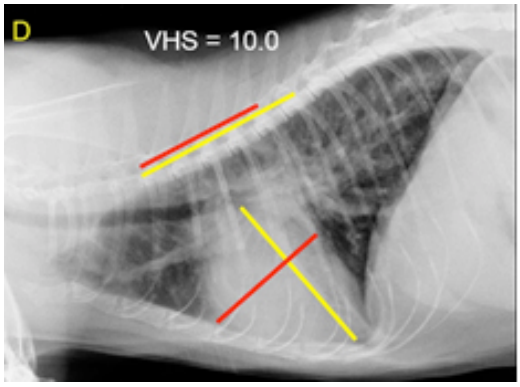

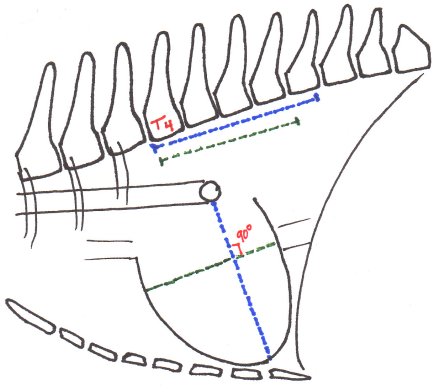

Cardiac Shape

The shape of the heart can be evaluated in a number of ways, on either the lateral view or the DV/VD view. For the DV/VD view, the heart is often likened to a clock face, and structures are noted relative to the position of numerals on the clock face. The aorta is located at the 12-1:00 location, the pulmonary artery at the 2:00 location, the left auricular appendage at the 2-3:00 site, and the left ventricle usually spans from the 3 to 5:30 or 6:00 location. The right ventricle spans from 5-6:00 site to the 9:00 position and the right atrium usually accounts for changes in the cardiac silhouette at the 9-11:00 spot. On the lateral view, the heart can roughly be divided into quadrants by a drawing a line from the carina to the left ventricular apex, with a second line perpendicular to the first which bisects the heart from top to bottom. With this scheme, the left atrium sits in the caudodorsal quadrant, the left ventricle in the caudoventral quadrant, the right atrium in the craniodorsal quadrant, and the right ventricle in the cranioventral quadrant. When looking at the vertical line from carina to apex, when there is considerably more heart cranial to this line the right heart enlargement in present. Left atrial enlargement is almost always notable in dogs with left sided congestive heart failure (pulmonary edema). Marked cardiomegaly can also result fro either pericardial effusion or tricuspid valve dysplasia. In dogs with pericardial effusion, the shape of the heart is often very round, especially on the DV or VD view, and the edges of the heart are often very clear or crisp, owing to lack of cardiac motion artifact.

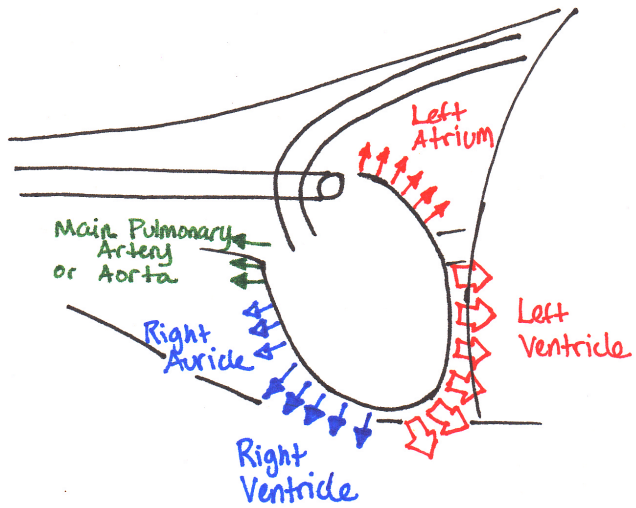

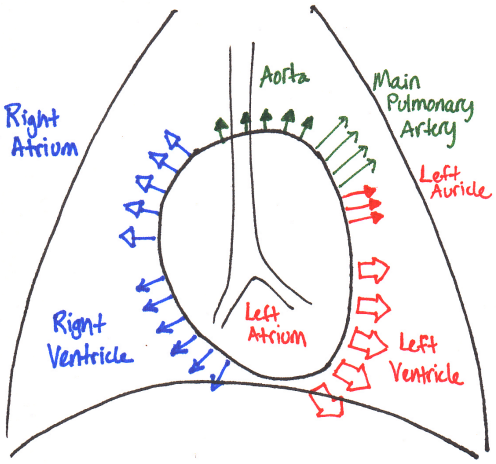

Great Vessels and Pulmonary Vasculature

The aorta can become enlarged, especially cranial to the heart, in animals with aortic stenosis or in cases with systemic hypertension or in aged cats. Small aortic size in the mid-thoracic aorta on the lateral view is often seen in animals with low cardiac output. The caudal vena cava becomes enlarged in cases with pericardial effusion or right-sided congestive heart failure. The ratio of the dimension of the caudal vena cava to the aorta can be used as a guide, with most normal animals having a CVC/Ao ratio of less than 1.5. In most animals with right sided cardiomegaly and an enlarged caudal vena cava, there is also both hepatomegaly on exam or radiographs and the jugular vein is either distended or there is a positive hepatojugular reflux. The pulmonary arteries and vein can also provide useful information about hydration status and cardiopulmonary health. Small pulmonary arteries and vein, especially with relatively dark lung fields and/or a small cardiac silhouette and small cava, often indicates hypovolemia. When the pulmonary vein is enlarged then left sided CHF is likely present or imminent. Pulmonary vein enlargement and tortuosity is often seen in cats on the lateral thoracic radiograph and this finding is often associated with marked left atrial enlargement. Cats with left sided CHF often have enlargement of both pulmonary arteries and pulmonary veins. When the pulmonary arteries alone are enlarged then pulmonary hypertension may be present. Enlargement of the main pulmonary artery and the PA segment alone can be seen with many cause of pulmonary hypertension, while enlargement of these segments combined with tortuosity of the distal pulmonary arteries and blunting of vessels is more common in dogs with heartworm disease. Enlargement of both the pulmonary artery and vein may indicate fluid overload, or the presence of a left-to-right shunting congenital cardiac defect.

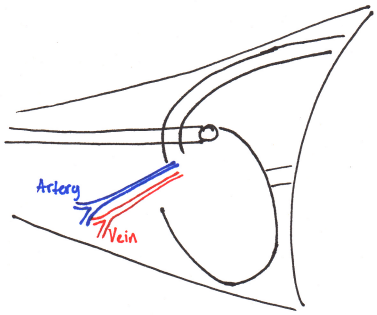

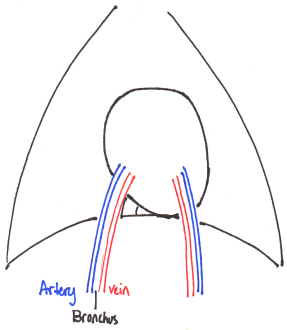

Pulmonary Radiographic Patterns

Radiographic patterns that may be detected upon thoracic radiography include bronchial, interstitial, alveolar and vascular. In many clinically significant diseases, there is a combination of patterns. It is prudent to review the patterns that are seen and to consult with regularly with a radiologists and cardiologists. Appropriate interpretation of radiographs requires a combination of film interpretation with the signalment, progression of disease, and clinical signs. Following radiographic assessment, clinicians should be prepared to evaluate what further clinical testing (if any) is required.

Alveolar Pattern

Alveolar disease is readily recognized by the appearance of air bronchograms, which develop due to the inherent contrast between aerated bronchi and fluid-filled lung parenchyma. Alveolar disease most commonly represents pneumonia,

pulmonary edema, pulmonary hemorrhage or pulmonary contusion. Rarely, malignancy may have focal alveolar disease, specifically with malignant histocytosis.

Pneumonia in dogs is mostly commonly associated with an alveolar pattern located in a cranioventral location and may be associated with a gas-dilated esophagus (megaesophagus). Some pneumonias are diffuse throughout the lung parenchyma, and this is especially true of community acquired pneumonia (i.e., non-aspirational pneumonia). Clinically, pneumonias are most often associated with lethargy, fever, cough and nasal discharge. Animals will often have a history of vomiting or other risk factors for aspiration such as laryngeal paralysis. Puppies, particularly those from pet stores are commonly affected with severe bronchopneumonia associated with the infectious tracheobronchitis syndrome. Importantly, cats with suspected pneumonia often have either concurrent asthma or congestive heart failure (instead of pneumonia).

Pulmonary edema may be cardiogenic or non-cardiogenic. In the early stages of pulmonary edema, fluid may only be appreciated as a heavy interstitial pattern. As the fluid progresses, the alveolar spaces fill in with edema and the radiographic pattern becomes alveolar. In large breed dogs, the lymphatics flow along side the bronchi and a bronchial pattern may be evident prior to the development of overt alveolar edema. Questions for the practitioner following the identification of a radiographic pattern suspected to be pulmonary edema include a decision on whether the patter n is a result of cardiogenic or non-cardiogenic pulmonary edema. In cardiogenic pulmonary edema, the cardiac silhouette is enlarged and left atrial enlargement may (should) be appreciated. Pulmonary veins are often engorged, and edema fluid in dogs with heart failure is usually perihilar. In cats, cardiomegaly is often although not always appreciated and edema distribution may be patchy. Causes of non-cardiogenic edema include upper airway obstruction or seizures. In these cases, edema is most commonly appreciated in the dorsal caudal regions of the lungs. It may develop peracutely following relatively benign conditions such as pulling on a choke collar or struggling during a bath. Non-cardiogenic edema may also develop as part of an inflammatory lung condition such as acute lung injury (ALI) or acute respiratory distress syndrome (ARDS). In these cases the medical history should help to pinpoint the diagnosis.

Pulmonary contusion is another common cause of focal alveolar infiltrates. Generally, the diagnosis is straight-forward based upon the medical history. However, in some cases, the trauma was unobserved. Systemic evidence for trauma includes elevated liver enzymes, particularly ALT and AST, ventricular ectopy and external wounds or frayed toe nails.

Interstitial Pattern

Interstitial diseases represent those conditions that are not alveolar or bronchial. The lung interstitium may fill with inflammatory products, edema, neoplasia or fibrosis. Interstitial diseases should not mask anatomy meaning that you should be able to see regional vessels and borders of the heart or diaphragm. If warranted, sampling from the interstitium is performed via a surgical or thoracoscopic lung biopsy or via a fine needle lung aspirate. Older dogs may have a heavy interstitial pattern without obvious pulmonary functional abnormalities. In recent years, the existence of a form of naturally-occurring pulmonary fibrosis (interstitial lung disease) in dogs and cats has been recognized. Significant questions for clinicians managing patients with interstitial lung disease include what testing should be done to establish a diagnosis and what therapies will relieve clinical signs. Biopsy requires a major intervention, while fine needle lung aspirates carry some risk and are often non-diagnostic. With the advances in imaging technology, the high-resolution CT scan is growing in popularity as a definitive aid in identification of the underlying pathophysiology.

Bronchial Pattern

A bronchial pattern represents the final form on pulmonary infiltrate that may be detected upon thoracic radiography. Bronchial infiltrates represent disease in the medium to larger airways. The most common cause of bronchial patterns are allergic and parasitic diseases. Dogs not uncommonly develop eosinophilic bronchopathy (bronchitis) as evidenced by a marked bronchointerstitial pattern and a large number (often in excess of 20,000) of circulating eosinophils. Cats are often affected with asthma or chronic bronchitis. Due to difficulty during expiration, thoracic radiographs will also commonly appear hyperinflated with flattening of the diaphragm due to air-trapping. Testing for heartworm disease and respiratory parasites is indicated, and repeated heartworm testing many months down the road might also be helpful to identify animals in an early stage of heartworm infection. Airway sampling via a tracheal wash is useful for documentation of pulmonary eosinophilia and occasionally for identification of lung worms. Many dogs and cats with inflammatory bronchial disease respond favorably to anti-inflammatory glucocorticoids.

Pleural Space Disease

Pleural space disease may be divided into fluid and air. Pneumothorax is often associated with trauma, but may also develop spontaneously due to bulla or bleb. Pleural effusion is most easily appreciated on a DV exposure by the diaphragm or in-between the lung lobes. From a cardiology perspective, pleural effusion represents right sided heart failure either as a primary disease or as part of progressive L-CHF (i.e., biventricular CHF). Heartworm disease at times may causes pleural effusion but more often R-CHF is associated with ascites. Older cats with cardiomyopathy appear more likely to form pleural effusion than younger cats. Also importantly, chronic pleural effusion, especially chylous or inflammatory effusions, may

lead to chronic pleuritis which can be noted by rounding of the edges of the lung lobes; this finding may significantly increase the risk of iatrogenic pneumothorax when the patient is tapped.

ECHOCARDIOGRAPHY

The growing availability and utility of ultrasonography is a vital aspect of improving patient care. The early identification of specific cardiac and non-cardiac illness is likely to improve outcome.

These are the standard right parasternal short axis views, with tips on how to obtain them.

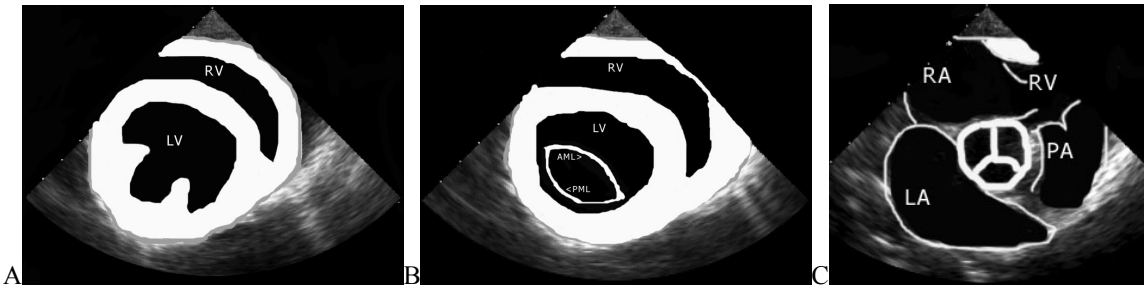

Short Axis of LV (A)

- Place probe perpendicular to chest wall over the cardiac notch; look for left ventricle (LV) and right ventricle (RV).
- Evaluate for vigor of contractility, rhythm (ectopy is fairly easily to appreciate as either early or late beats), volume status, pericardial effusion, pleural effusion, myocardial hypertrophy (particularly of the left ventricle) or dilation.

Short Axis of LV with Mitral Valve (B)

- Angle or slide probe a little dorsally
- Notice thickness and mitral valve motion; look for vegetations
  AML – Anterior mitral leaflet, PML – Posterior mitral leaflet

Short Axis of Ao/LA/Pulmonic Outflow Tract (C)

- Angle or slide probe a little more dorsally
- Note size of Ao to LA (normal is 1:1-1.25)
- Note aortic valves (thickness, vegetations)
- Note pulmonic valve, size of PA

Identification of Pleural or Pericardial Effusion

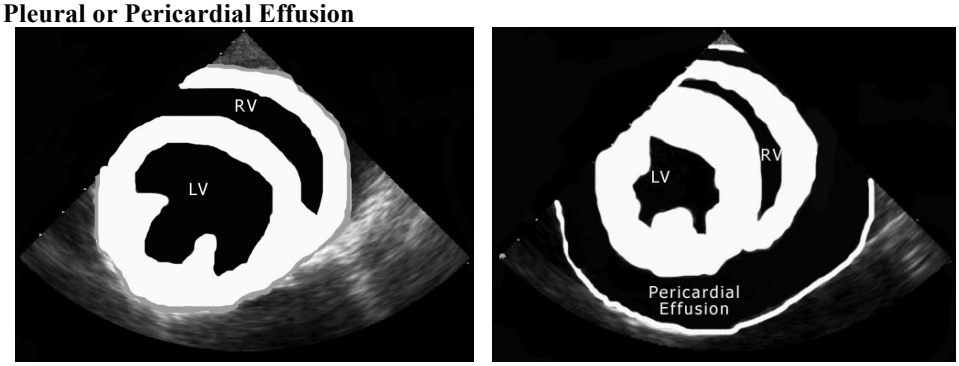

Common presenting complaints for animals with cardiac tamponade include collapse, syncope, weakness, abdominal distention, tachypnea or dyspnea, vomiting and anorexia. Physical examination may reveal muffled heart sounds, weak arterial pulses, pulsus paradoxus, jugular vein distention, ascites or hepatomegaly, and pale mucous membrane with slow capillary refill time. The diagnosis of pericardial effusion is easily confirmed with echocardiography. The fluid-filled "echo-free" space between the pericardium and the epicardial surface of the heart is diagnostic of pericardial effusion. In most instances of collapse associated with pericardial effusion, the cardiac chambers are small and there is collapse during diastole of the right ventricle and right atrium indicative of tamponade. In the long axis view, diastolic collapse of the right atrium is most easily identified. A mass lesion can be identified as a cause for pericardial effusion near the heart base or right atrium in many dogs. The location for successful pericardiocentesis can be facilitated through the use of echocardiography, although ultrasound guidance in particular is not needed. Most often, pericardial effusion is associated with a neoplastic process; however, idiopathic disease, left atrial tear, and other diseases may also result in pericardial effusion.

Pleural effusion is found as a relatively echo-free density around the heart, however there is no pericardial sac surrounding the heart. There are often thin, wispy “fibrin tags” floating in pleural effusions, however this is rarely found in animals with pericardial effusion. To distinguish between pleural and pericardial effusion a few tricks can be done. First, alter

the depth such that the heart gets very "small" and search for a pericardial sac. Next, aim the ultrasound probe cranial and caudal to the heart in an attempt to locate and better characterize pleural effusion – more fluid can often be identified either in front of or behind the heart.

Assessment of Left Atrial Size

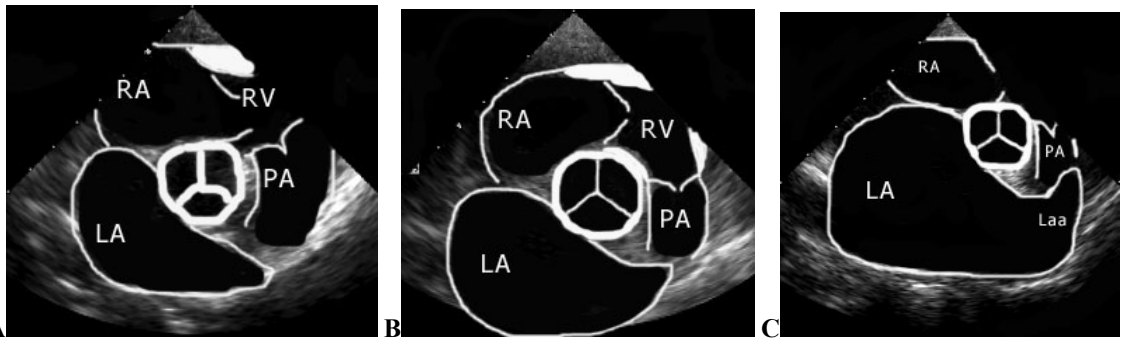

Congestive heart failure is often a differential diagnosis for dogs and cats with respiratory distress and radiographic pulmonary infiltrates. There are a number of ancillary tools and examination findings that can be useful in confirmation of a diagnosis of left-sided congestive heart failure. On physical examination many animals have either a murmur or gallop, tachycardia, ascites, jugular vein distention or cardiac arrhythmia supporting a diagnosis of CHF. NT-proBNP can also be used to help distinguish between cardiac and respiratory causes of dyspnea or cough. A quick echocardiographic exam can help guide clinical decisions relative to administration of diuretics or fluids. The most reliable indicator of left-sided CHF on the echocardiogram is enlargement of the left atrium. In the vast majority of dogs and cats with left-sided CHF there will be moderate to marked left arterial enlargement present on the echocardiogram. The echocardiogram on the left (A) documents the normal relationship between the aorta, in the center, and the left atrium (LA). Mild to moderate left atrial enlargement is noted on the center echocardiogram (B). Marked left atrial enlargement is noted on the right echocardiogram (C) as would be typical for most dogs and cats with left sided CHF. In the absence of left atrial enlargement, dyspnea and/or pulmonary infiltrates cannot be easily ascribed to cardiac disease and other differentials should be pursued. RA = right atrium, RV = right ventricle, PA = pulmonary artery, Laa = left auricular appendage.

Pulmonary Thromboembolism and Pulmonary Hypertension

Echocardiography can be useful to document the presence of pulmonary hypertension or pulmonary thromboembolism. In rare cases, a thrombus can actually be visualized within the right side of the heart or within the main pulmonary artery. Severe heartworm disease may result in visible heartworms in the right heart. In most animals with hypoxemia and pulmonary thromboembolism, some evidence of right ventricular enlargement will be present. In many animals, right ventricular enlargement is seen along with enlargement of the pulmonary artery. In animals with pulmonary hypertension or pulmonary thromboembolism, the pulmonary artery is often bigger than the aorta, the left ventricular cavity often appears small, and the left atrial cavity is often normal or small as well.

Cardiac Biomarkers

Natriuretic Peptides

The natriuretic peptides are a family of structurally similar genetically distinct proteins including atrial natriuretic peptides (ANP) and B-Type (or brain) natriuretic peptide (BNP, or NT-proBNP). These proteins are regulators of salt and water homeostasis and blood pressure and they cause natriuresis, diuresis, and balanced vasodilatation. Atrial natriuretic peptide (ANP) is chiefly produced in the atria. B-type natriuretic peptide (BNP) is also produced in the heart (especially in the ventricles) and is released into circulation in situations of cardiac hypertrophy or volume overload states. Upon release, the pre-molecule (pre-proBNP) is cleaved into active c-BNP and biologically inactive NT-proBNP. NT-proBNP is characterized by higher serum concentrations and a longer half-life and is the most studied clinical cardiac biomarker. Commercial assays for the natriuretic peptides are available and are species-specific (human assays cannot be used for analysis of BNP in veterinary patients). Normal dogs have very low levels of circulating ANP and BNP, and the levels rise modestly with mild to moderate cardiac disease, and they typically rise even further with the development of congestive heart failure. Clinical applications include assessment of the likelihood of CHF, determination of the presence or asymptomatic heart disease, and differentiation of cardiac from respiratory disease in the emergency setting. A bedside test in available for immediate qualitative results in cats, but there can be advantage to using the quantitative test, and at this stage only a quantitative test is available for dogs.

NT-proBNP can help identify cats with asymptomatic heart disease.

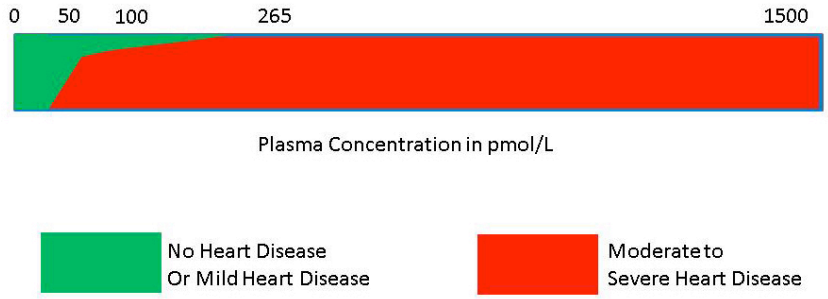

NT-proBNP can help determine whether cats with respiratory signs have CHF or lung disease

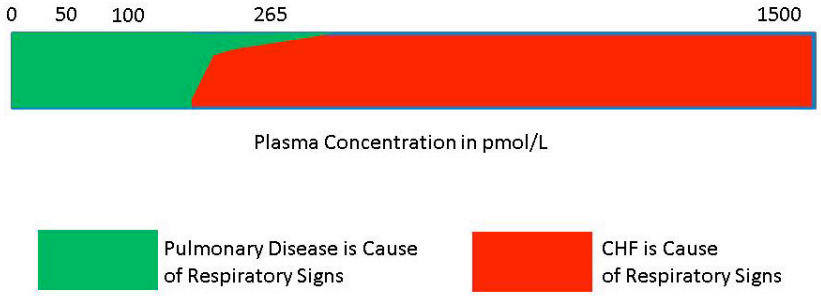

NT-proBNP has potential to be useful as a screening tool for occult DCM in Doberman pinscher dogs.

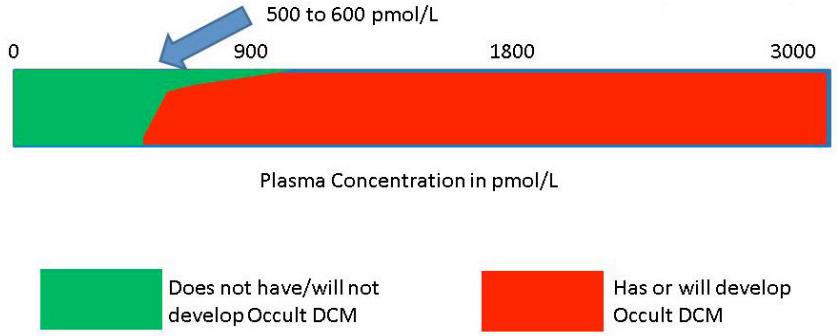

NT-proBNP can predict dogs with Degenerative Mitral Valve Disease that are likely to develop CHF in the next 6 to 12 months

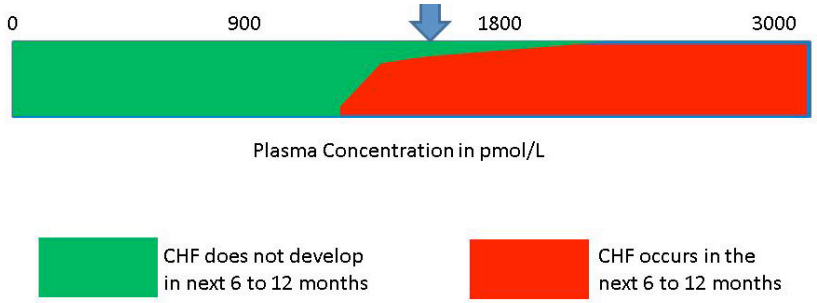

Cardiac troponins

Cardiac troponins, including cardiac troponin I (cTnI) and cardiac troponin T (cTnT) are diagnostic tests that are currently available and may offer some utility in identification of cardiac disease. These troponins are released in response to cardiac injury. Mild increases in cardiac troponins can be seen in dogs and cats with congestive heart failure and in cases with ongoing cardiac damage. Severe elevations occur in setting of acute myocardial injury. Cardiac troponin I looks to be better than cTnT for veterinary species. Cardiac troponin I cannot be used in dogs to reliably discriminate between cardiac and respiratory causes of shortness of breath or cough. Cardiac troponin I looks to perform a bit better in cats, but is not as accurate as NT-proBNP. The combination use of cardiac troponins and natriuretic peptides might prove to be very helpful in the future.

1) This cat is suspected to have CHF. What is the correct vertebral heart size, based on the available pictures?

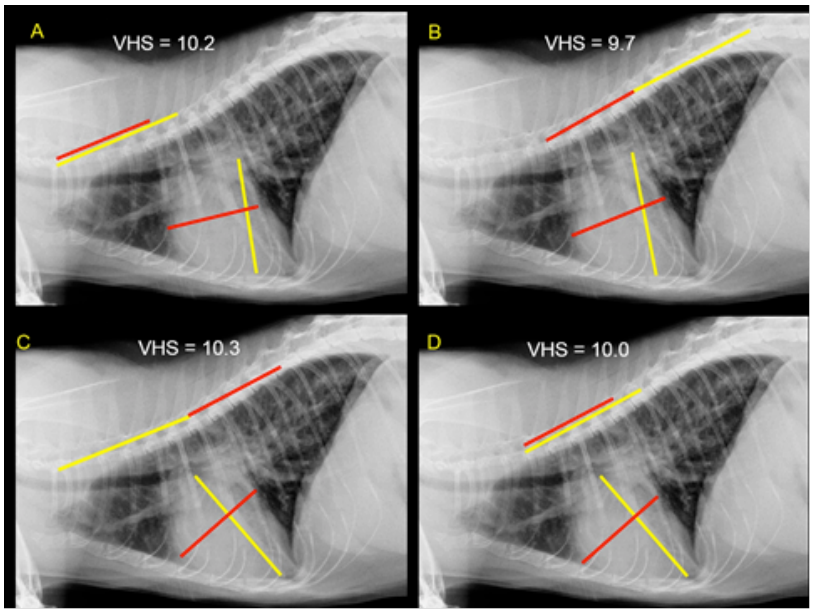

A. VHS = 10.2 v
B. VHS = 9.7 v
C. VHS = 10.3 v
D. VHS = 10.0 v

2) NT-proBNP testing can help identify dogs with degenerative mitral valve disease who are at increased risk for development of CHF in the next 6 to 12 months.
   a. True
   b. False

3) NT-proBNP testing can help identify Doberman pinschers are risk for development of dilated cardiomyopathy.
   a. True
   b. False

4) A markedly elevated cardiac troponin I concentration would indicate that the animal has experienced a significant insult to the heart leading to cellular damage or death.
   a. True
   b. False

5) Most animals with cardiogenic pulmonary edema have a normal sized left atrium
   a. True
   b. False

6) The left atrium depicted below is:
   a. Normal in size
   b. Markedly enlarged

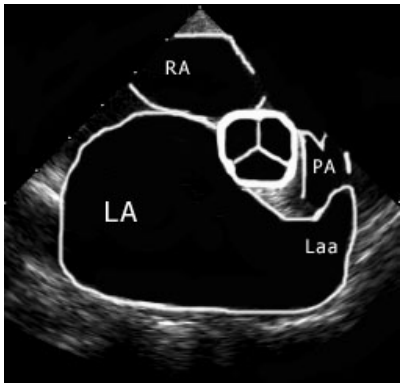

7) Enlargement of the pulmonary arteries with normal sized pulmonary veins is most consistent with:
    a. Left-sided CHF
    b. Pulmonary hypertension
    c. Hypovolemia
8) Pericardial effusion can be noted on echocardiography. This image documents pericardial effusion.
    a. True
    b. False

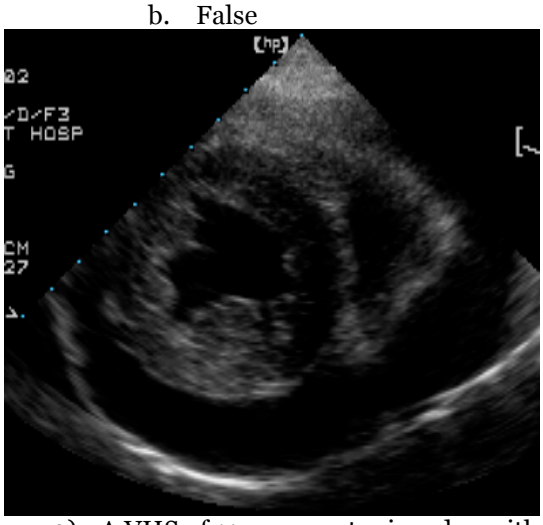

9) A VHS of 11.5 or greater in a dog with degenerative mitral valve disease might be:
    a. A signal that the dog is getting close to CHF
    b. A signal to start a diuretic like furosemide
    c. A normal value from most dogs
10) An alveolar pattern on thoracic radiographs usually means:
    a. That the animal has CHF
    b. That the alveoli are filled with blood, or purulent material, or cells, or fluid of some type
    c. That the animal has asthma
    d. That the animal likely has neoplasia