



Efficient Spay/Neuter Surgical Techniques

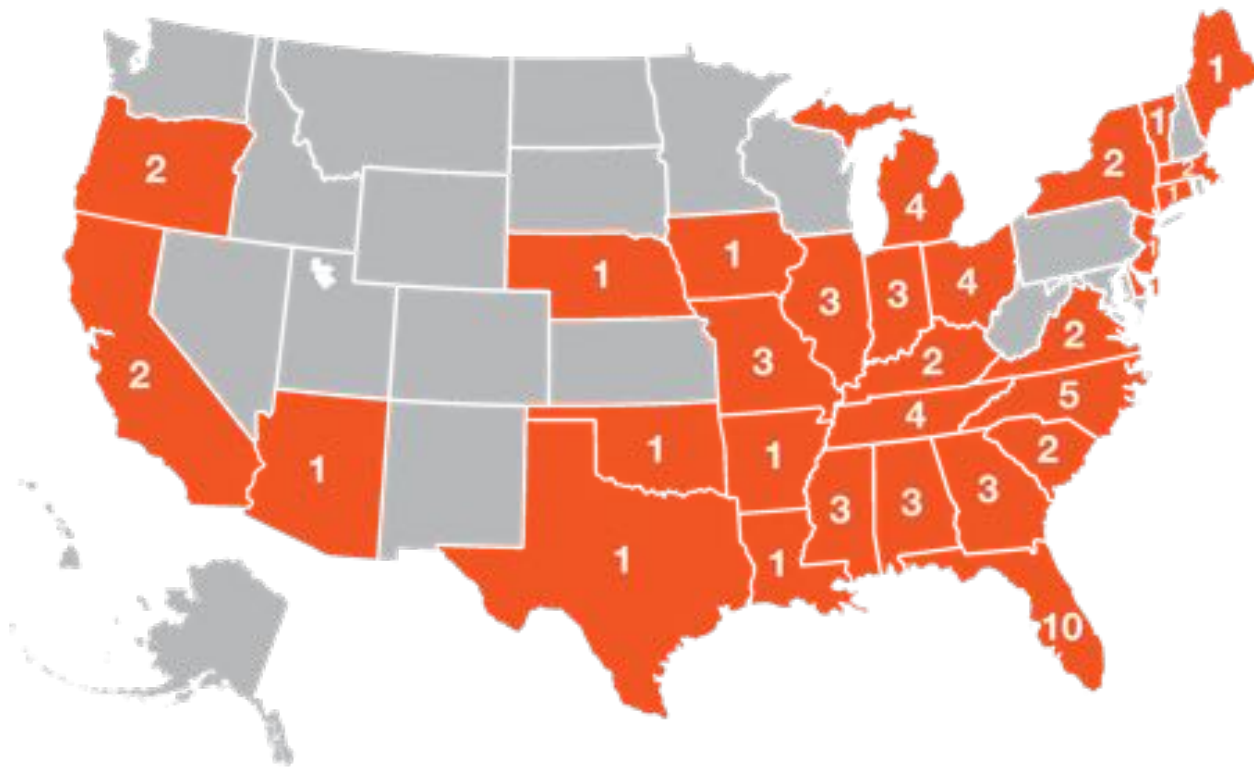
Karla Brestle, DVM

Senior Director of Medicine – ASPCA Spay/Neuter Alliance

Updated: 4/26/18

Proven Methods

- 166 clinics trained across the US & Canada
- 1 million+ companion animals are sterilized each year
- 1,328+ private veterinarians have completed training for CE

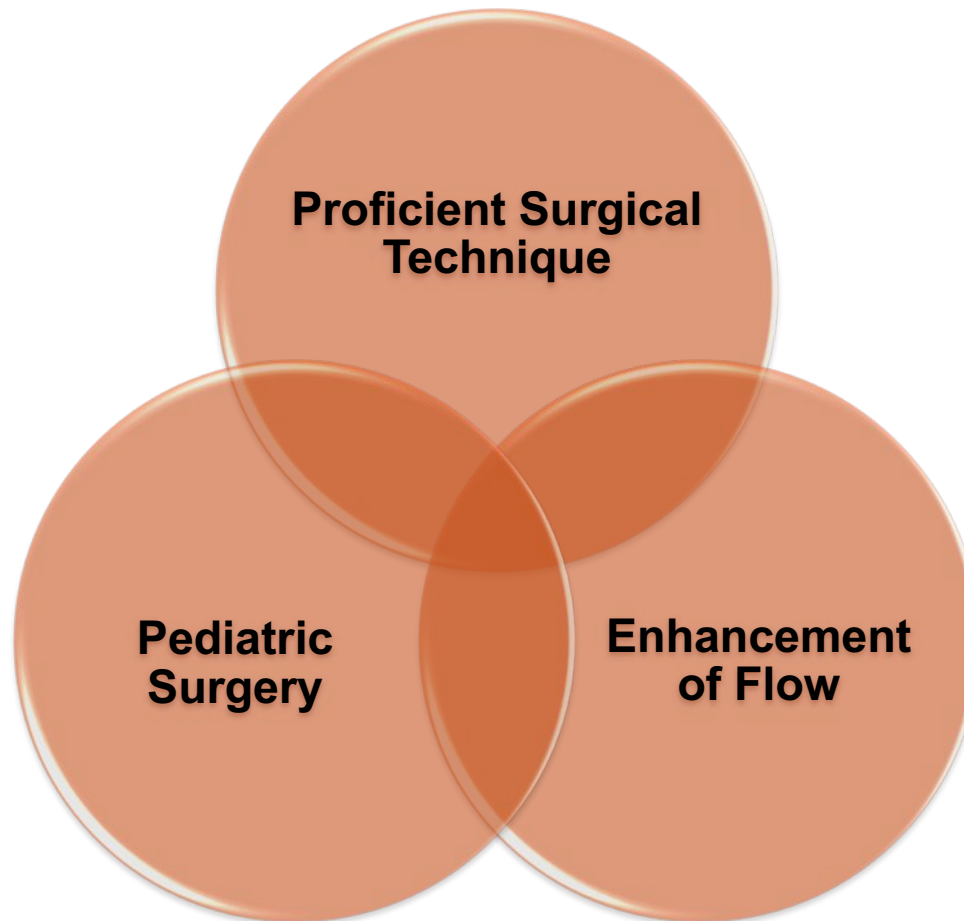


Enabling Local Veterinarians

- You know the need in your region best
- Empower individuals to take action for their own communities
 - Hands-on training in AVL
 - Obtain CE credit



Improving Efficiency in Spay/Neuter



Pediatric Surgery



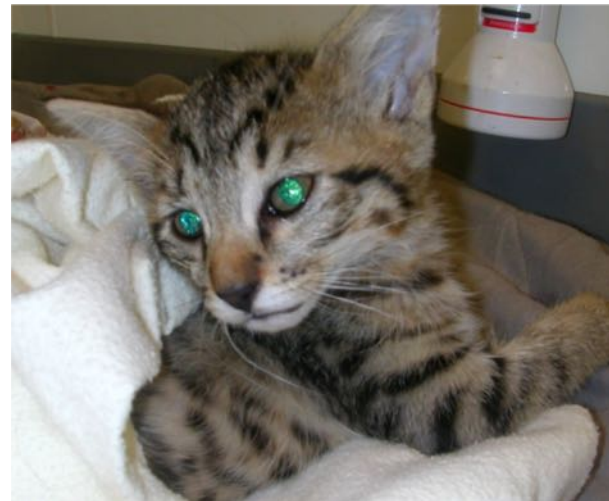Traditionally 6 Months

- Difficulty with this rule of thumb lies in that many cats may have their first heat at 4 months
- Thus waiting until 6 months to spay risks an accidental pregnancy

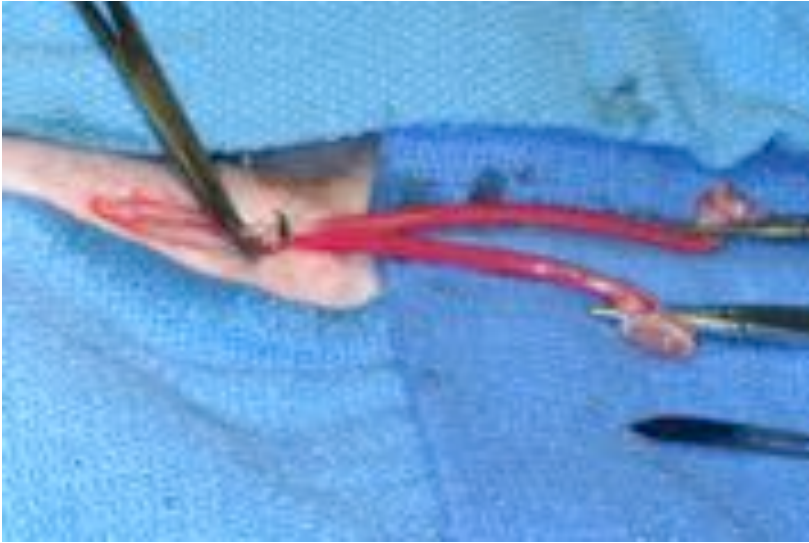


Advantages to Pediatric Spays

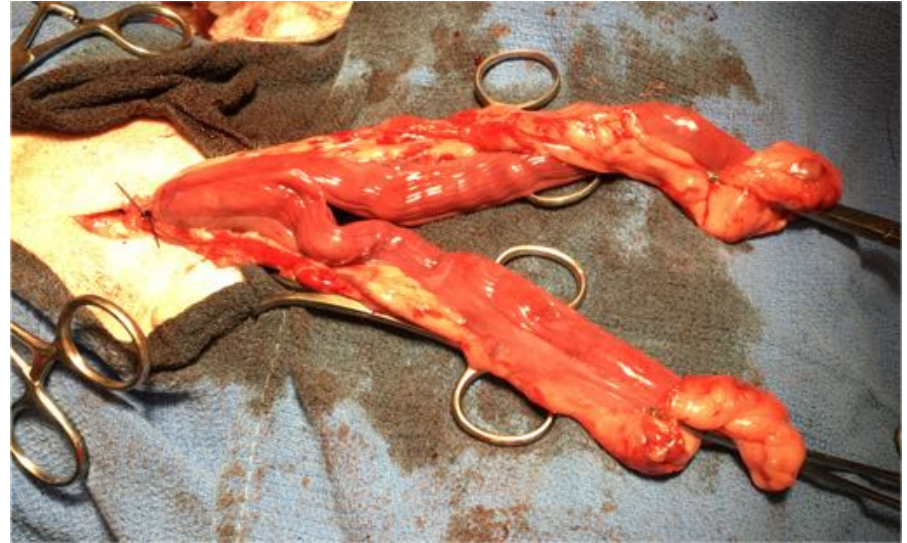
- Faster surgery time
 - Less fat
 - Less bleeding
 - More elastic tissues
 - Excellent visualization
 - Less suturing
- Faster recovery from anesthesia
- Faster healing



Less Stressful for Patient & Surgeon



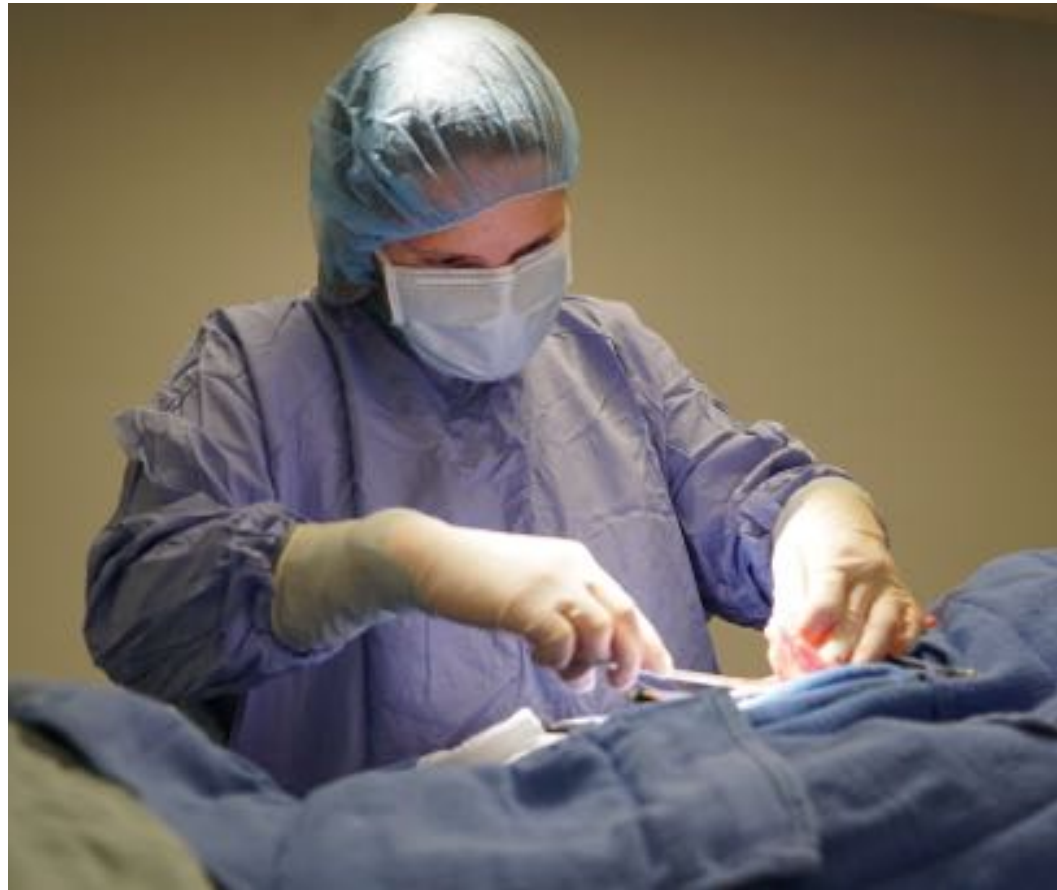Puppy



In-Heat Adult Dog

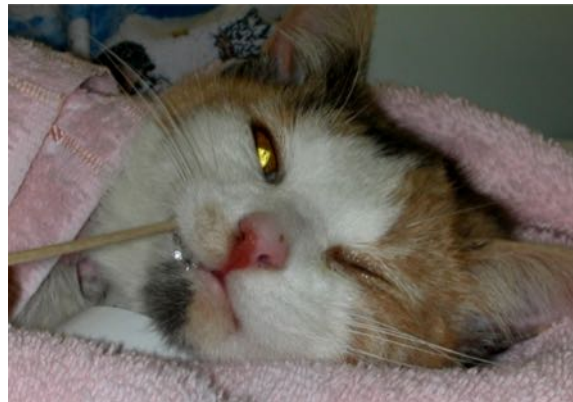
Peri-operative Concerns for Pediatric Patients

- Hypoglycemia
- Hypothermia
- Blood loss
- Stress
- Infectious disease



Avoiding Hypoglycemia

- Minimal stores of hepatic glycogen → risk for hypoglycemia
 - Avoid prolonged fasting
 - GI emptying time is very fast in puppies & kittens, so less chance for regurgitation/aspiration
 - Maximum 4 hours fasting (can “pre-Tx”)
 - Feed 1-2 tsp 15 mins after standing & small meal within 1-2 hrs
 - Karo syrup for “sugar lips” pre-op & post-op



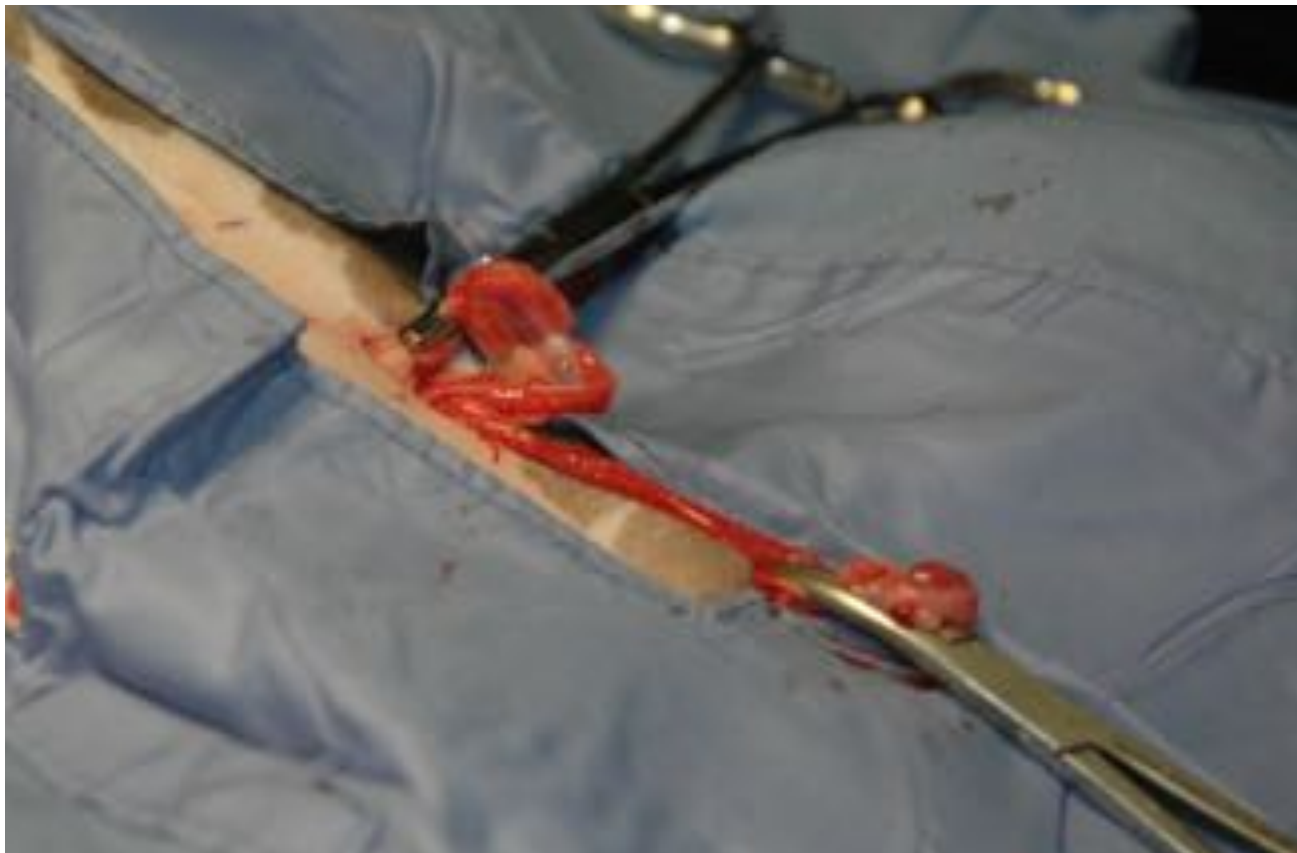
Avoiding Hypothermia

- Use towels & supplemental heat
 - Hot water blanket
 - Rice bag/sock
- Shave hair conservatively
- Avoid excess wetting of coat during prep
- Allow littermates to recover together
- Use shredded paper/towels in recovery cages
- Use of “space blankets”



Avoid Blood Loss

- Meticulous tissue handling
- Hemostasis

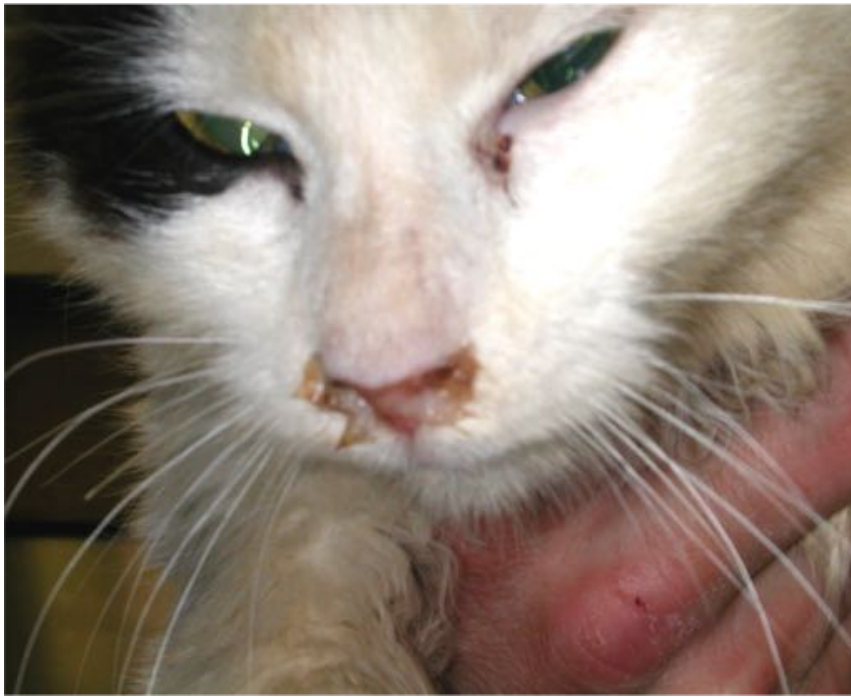

Avoid Stress

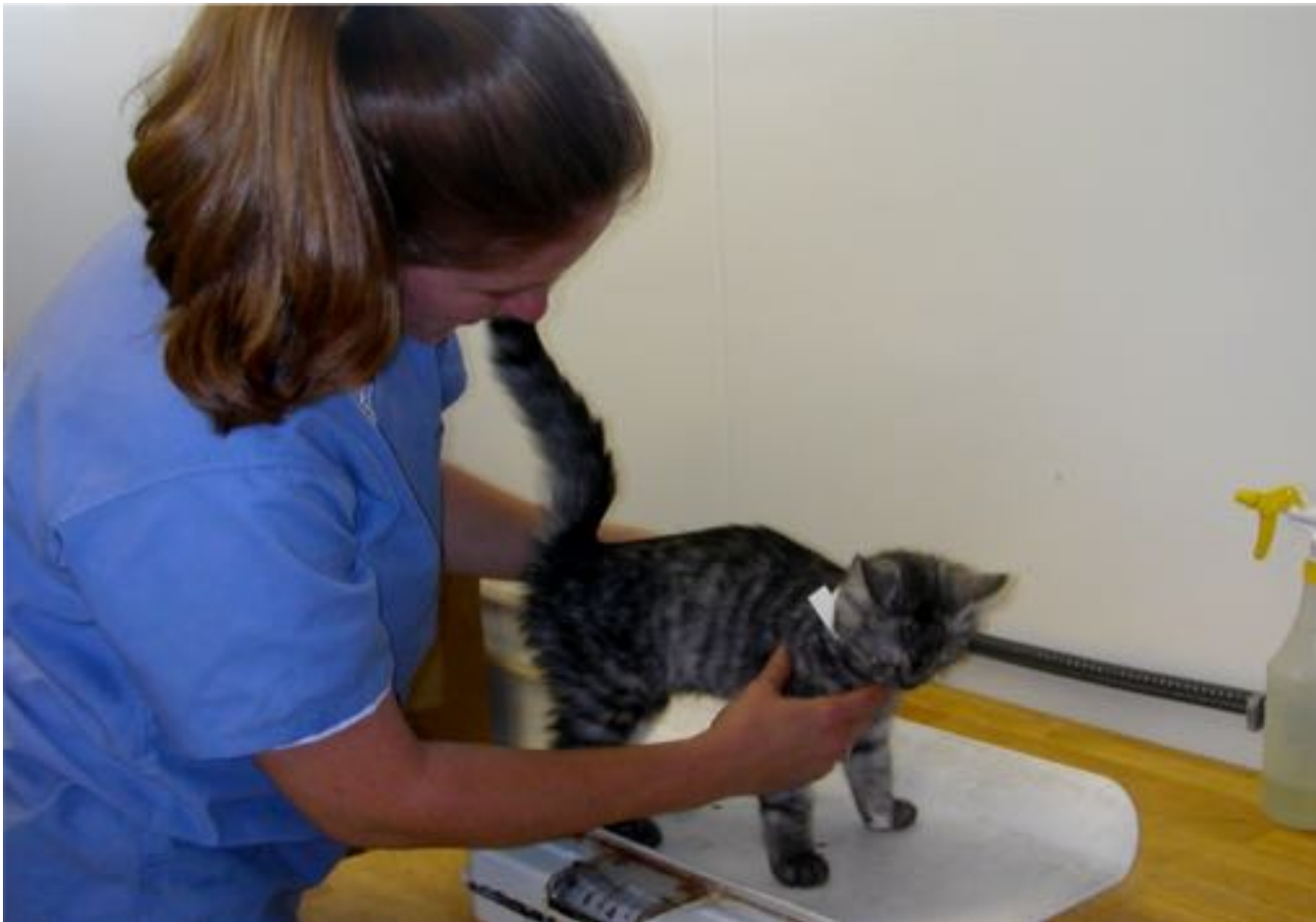- House littermates together



Infectious Disease

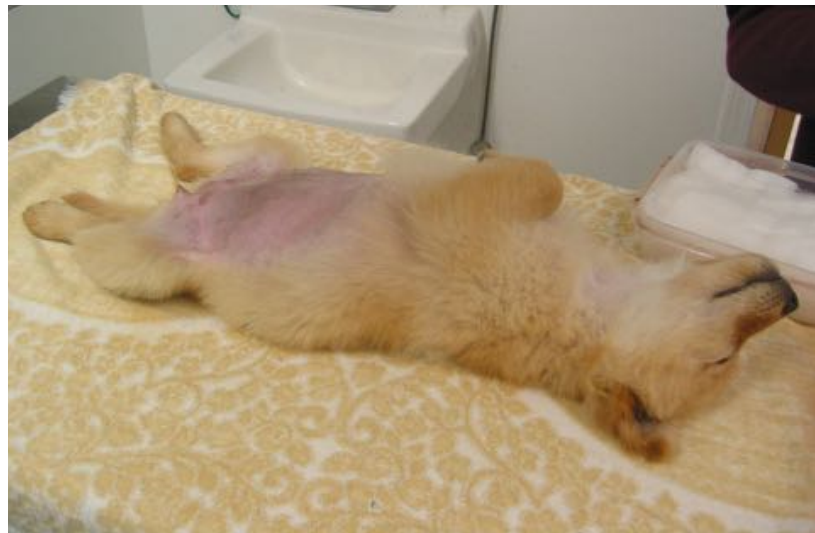
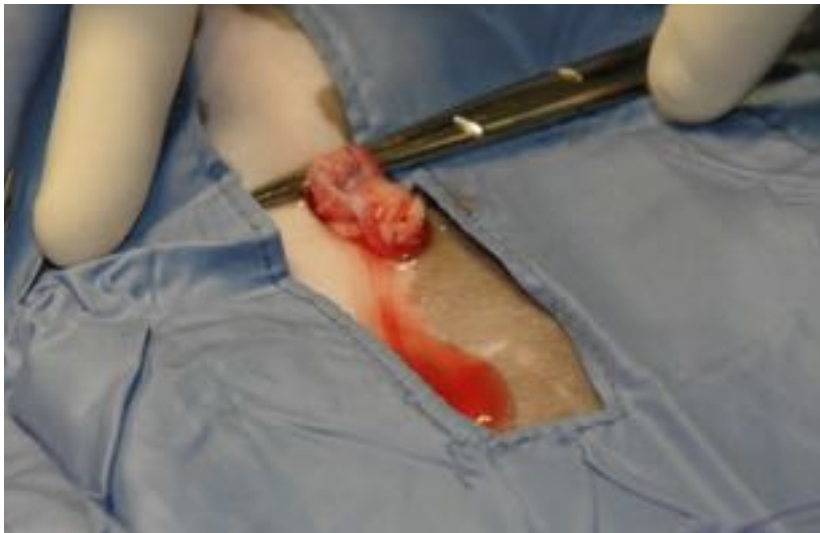
Accurate Weight

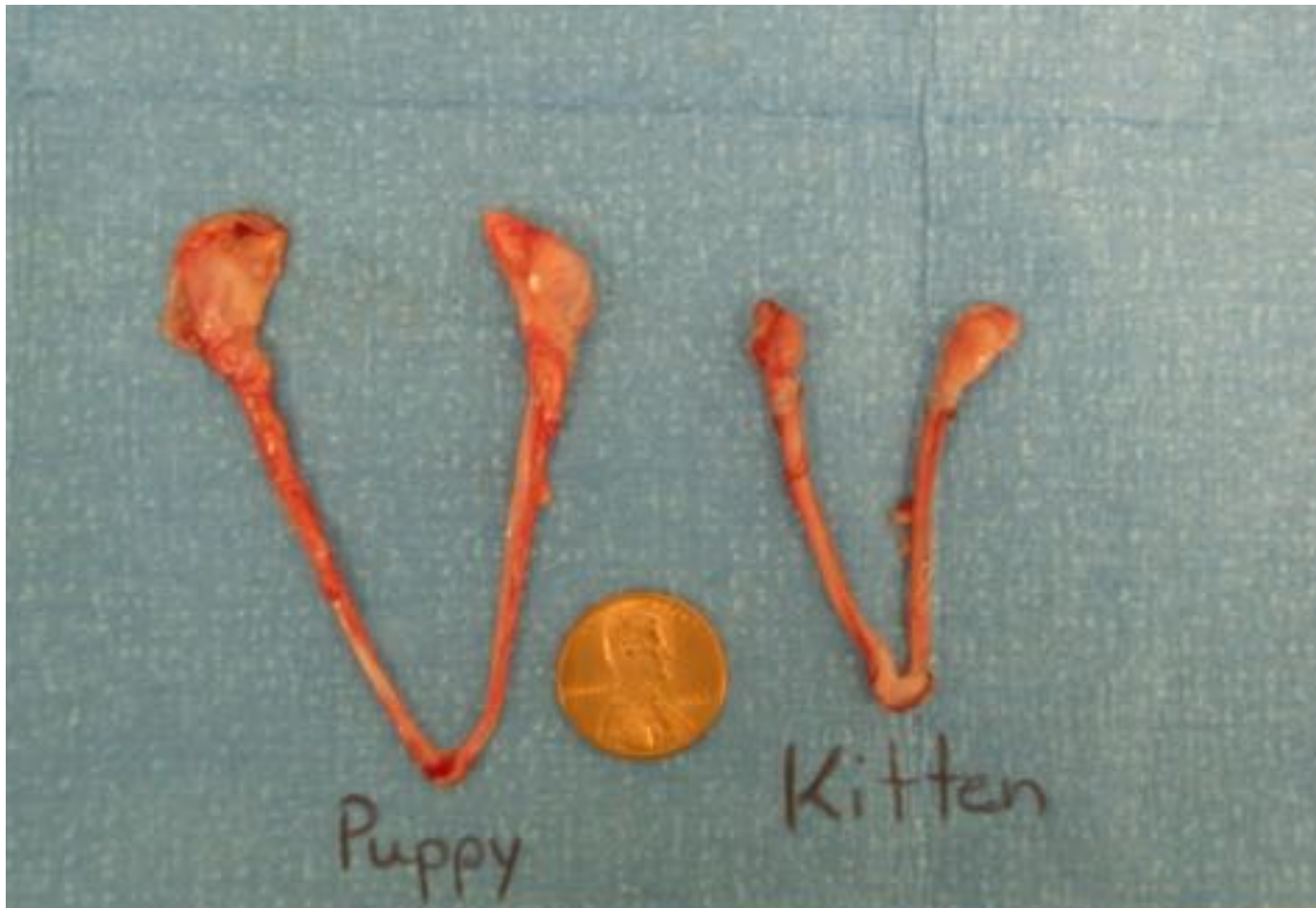

Puppy & Kitten Spays

- Ventral midline incision
 - Small (2 cm)
 - Midway between umbilicus & pubis
 - Slightly more cranial for puppies
- Expect abdominal fluid!



Puppy & Kitten Spays



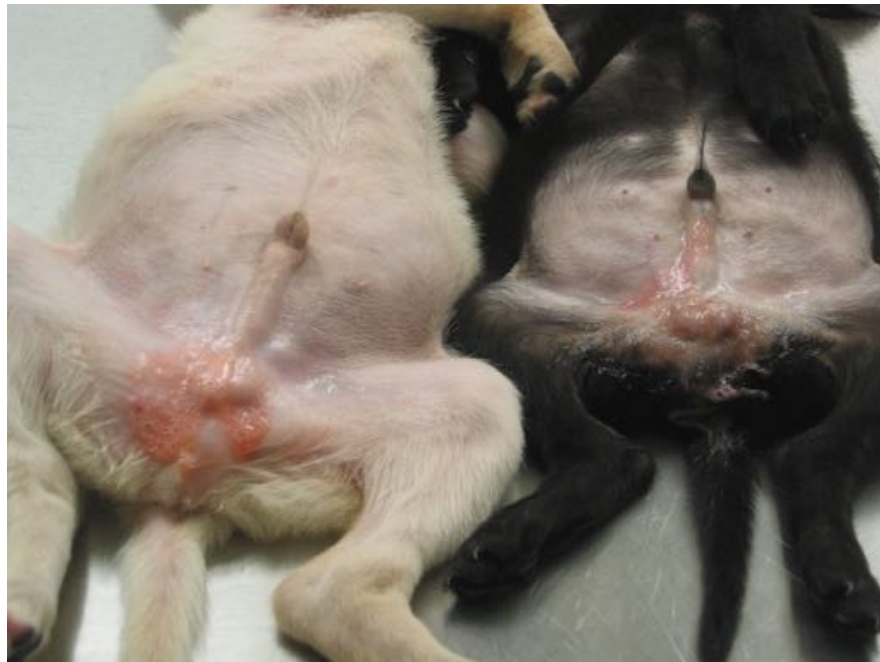Kitten Neuters

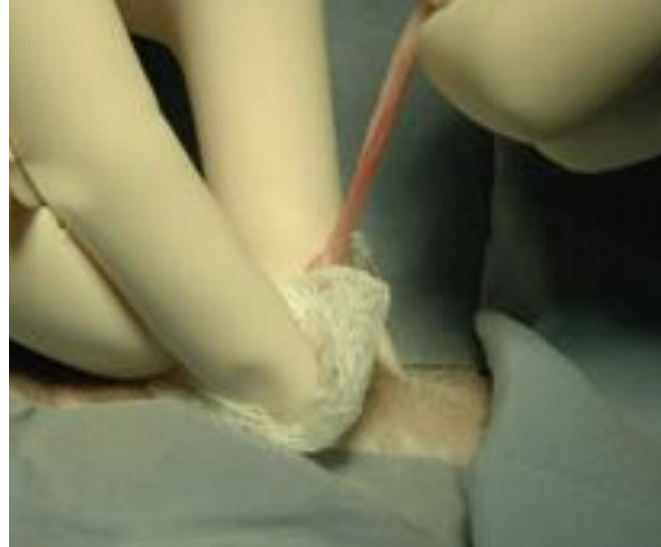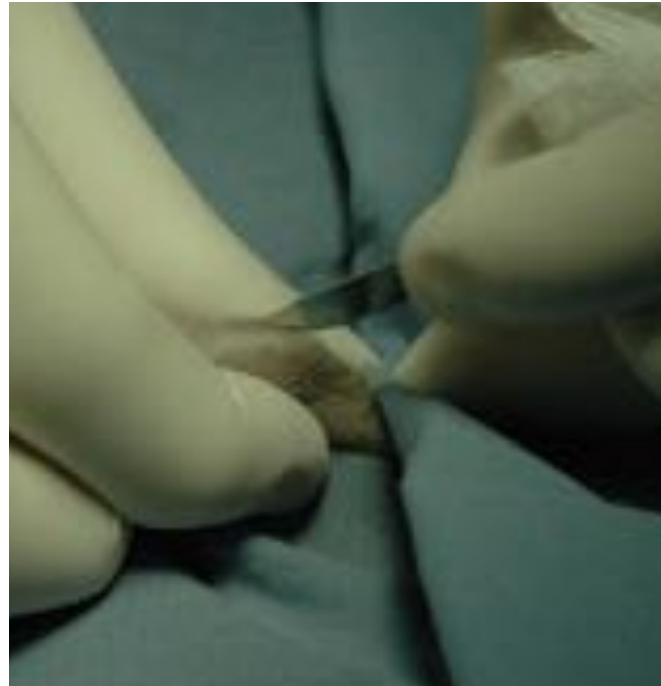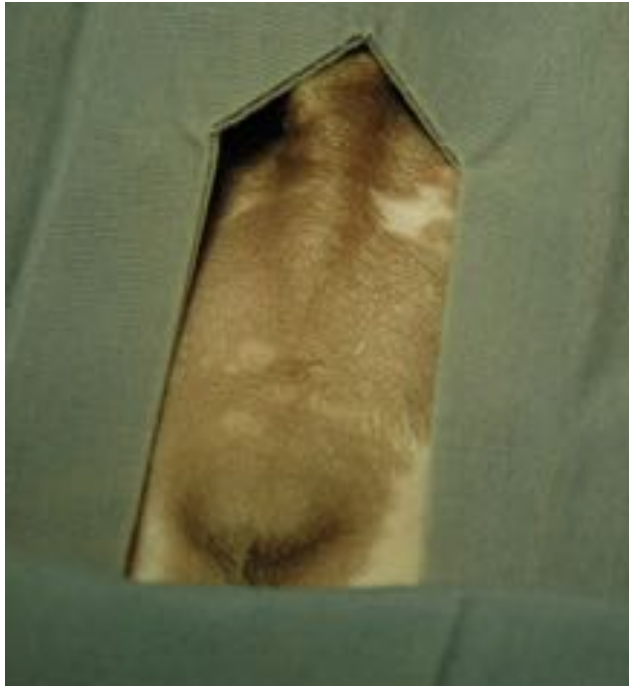- Scrotal incisions
- Closed technique
- Self ligatures
- No closure

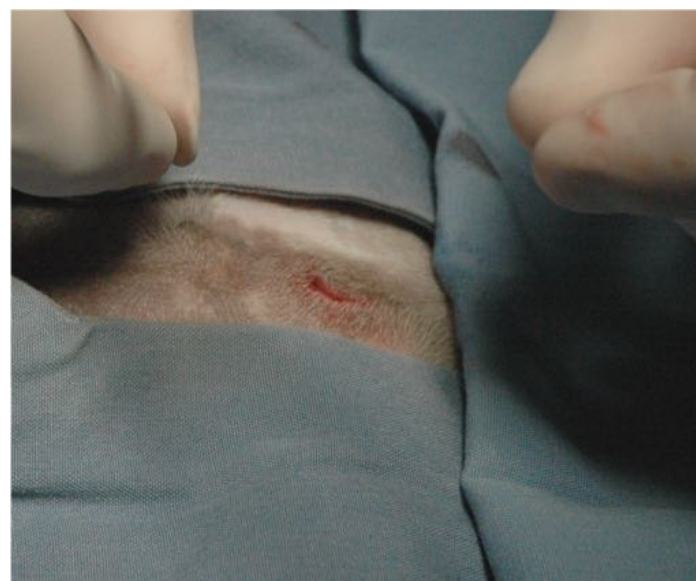
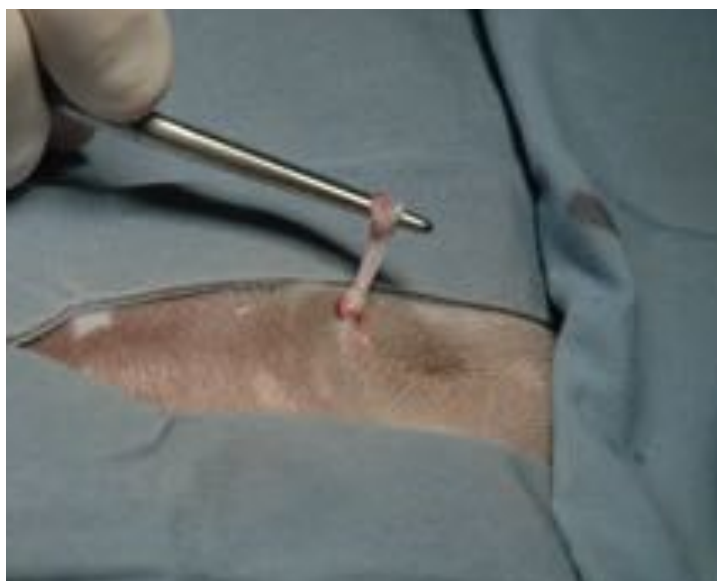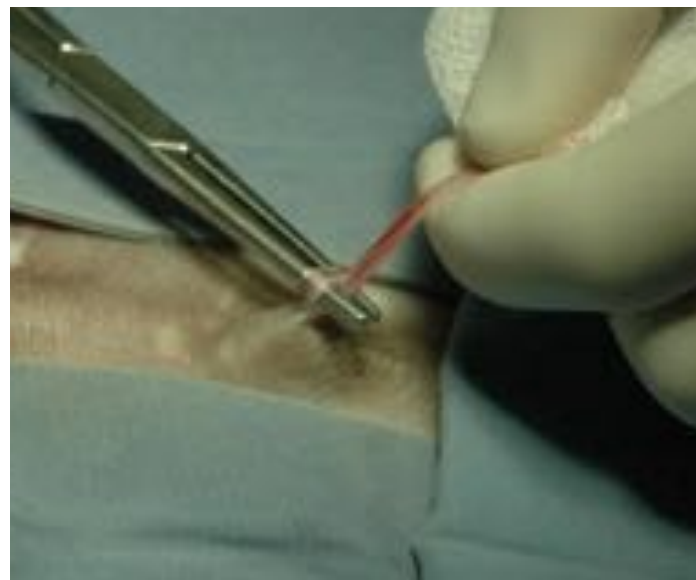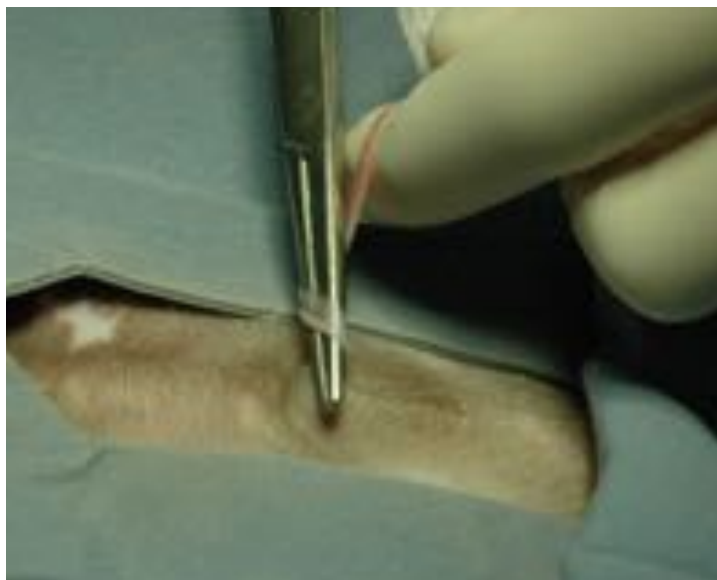


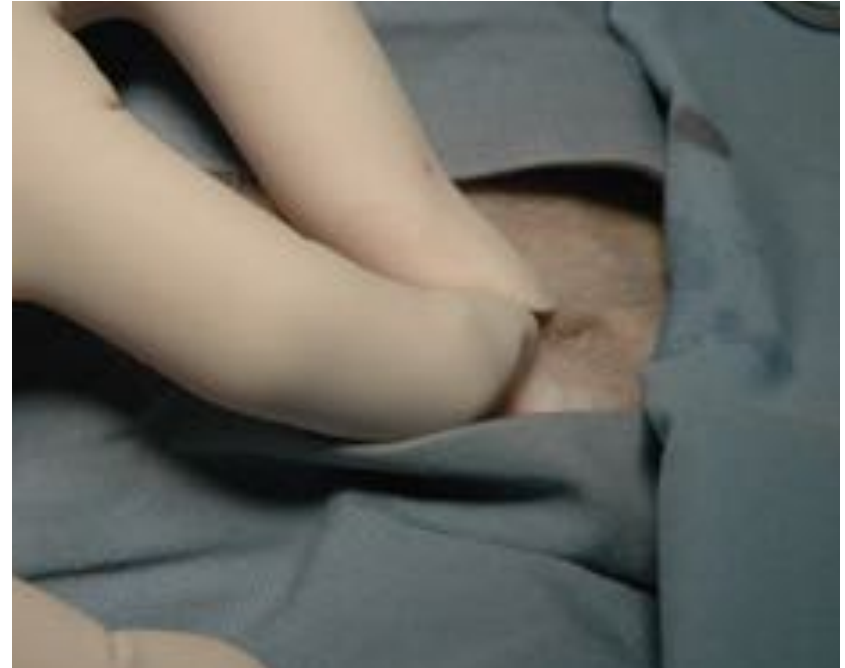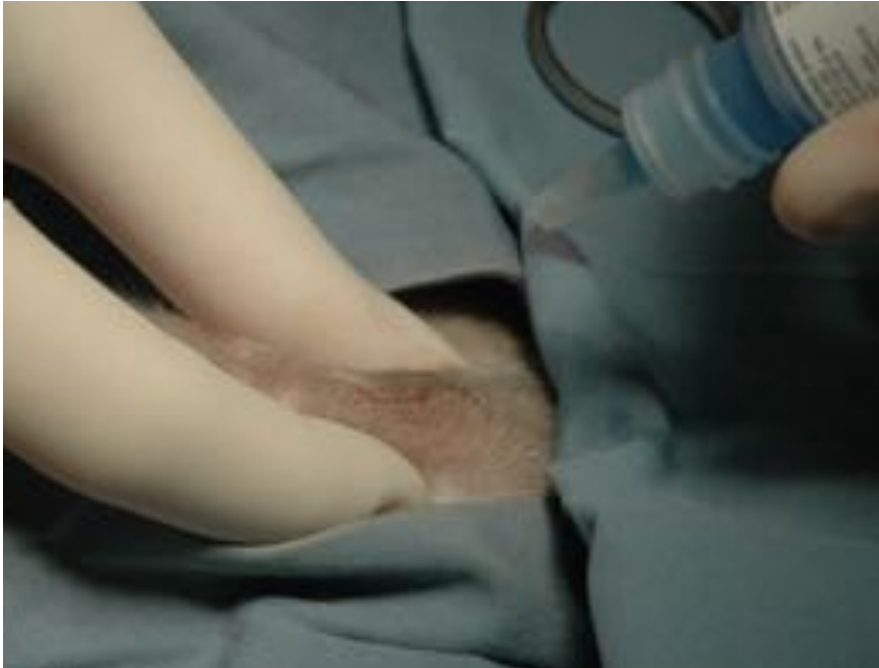Puppy Neuters

- Scrotal or pre-scrotal incision
- Closed technique
- Self ligatures
- Close with tissue glue

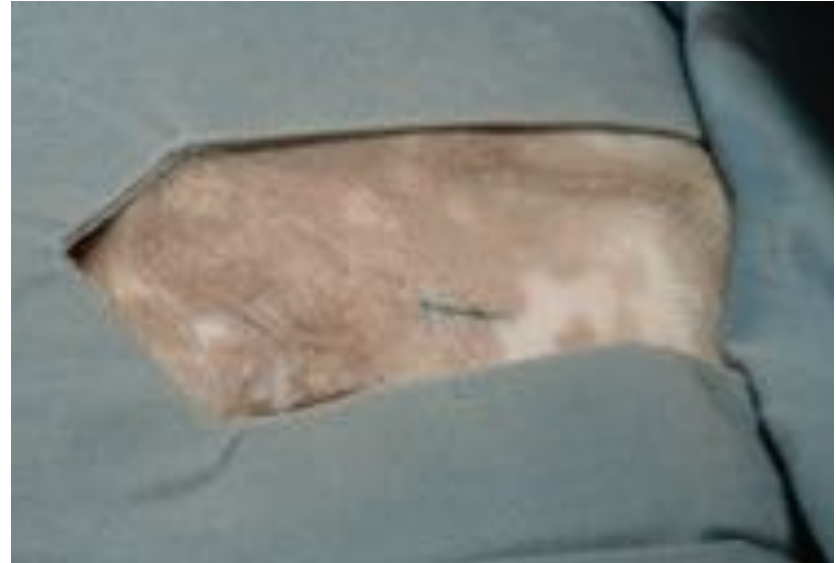
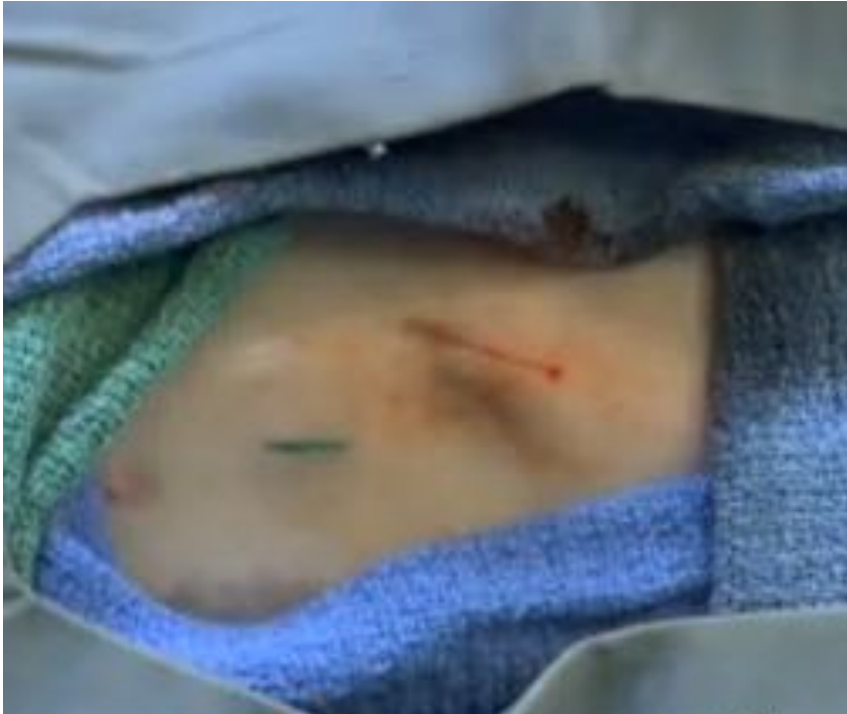




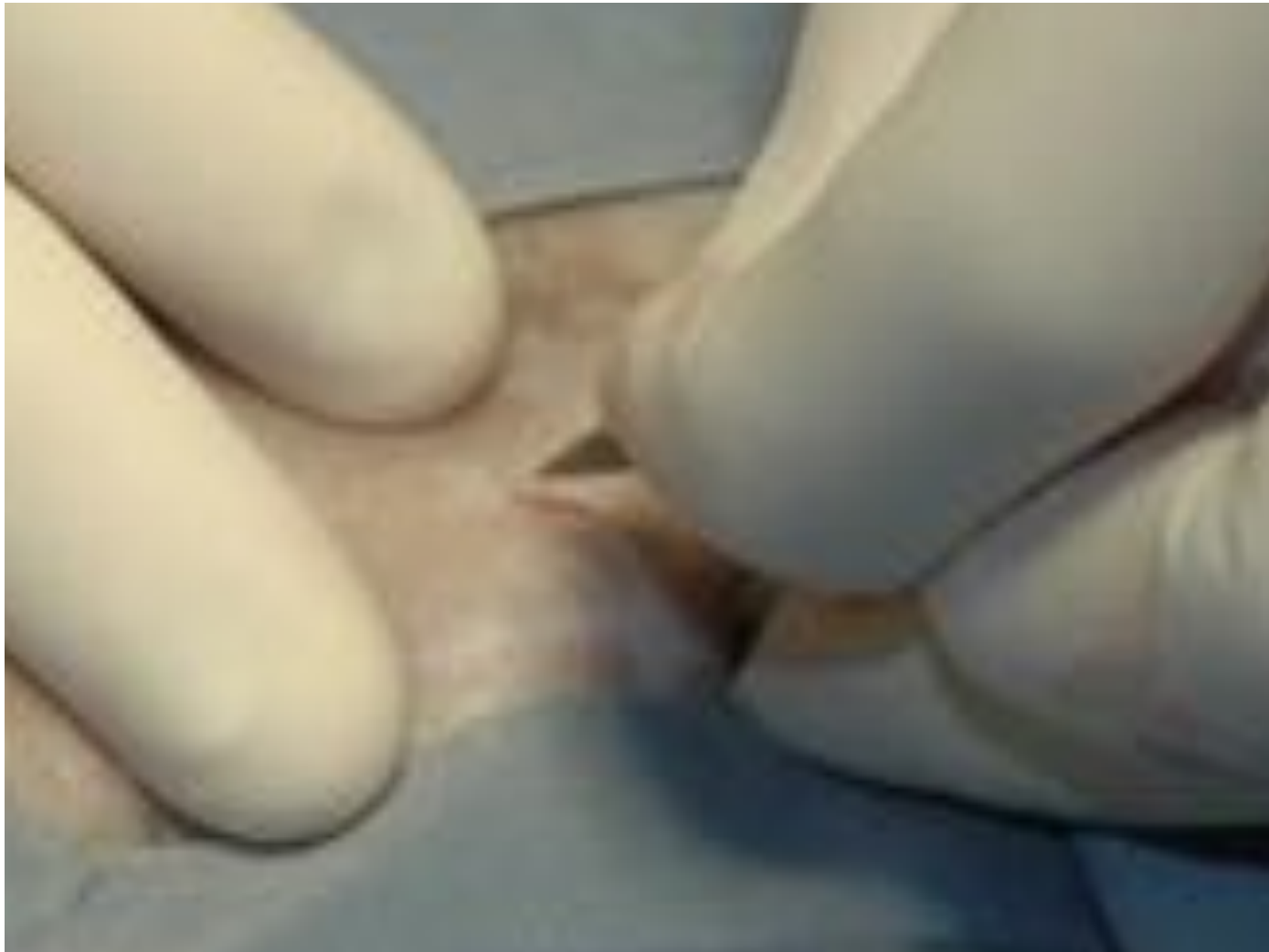

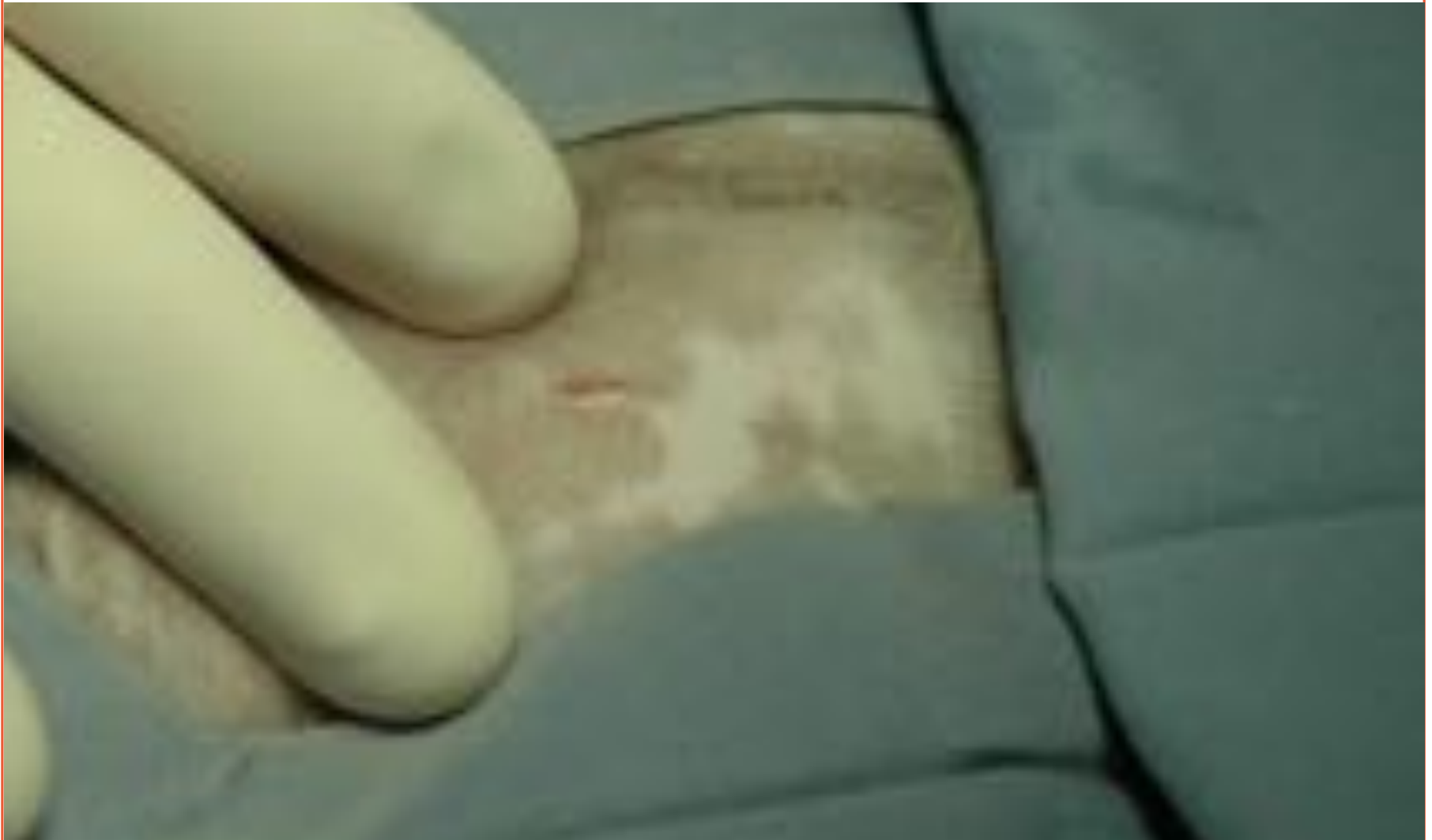
Tattooing



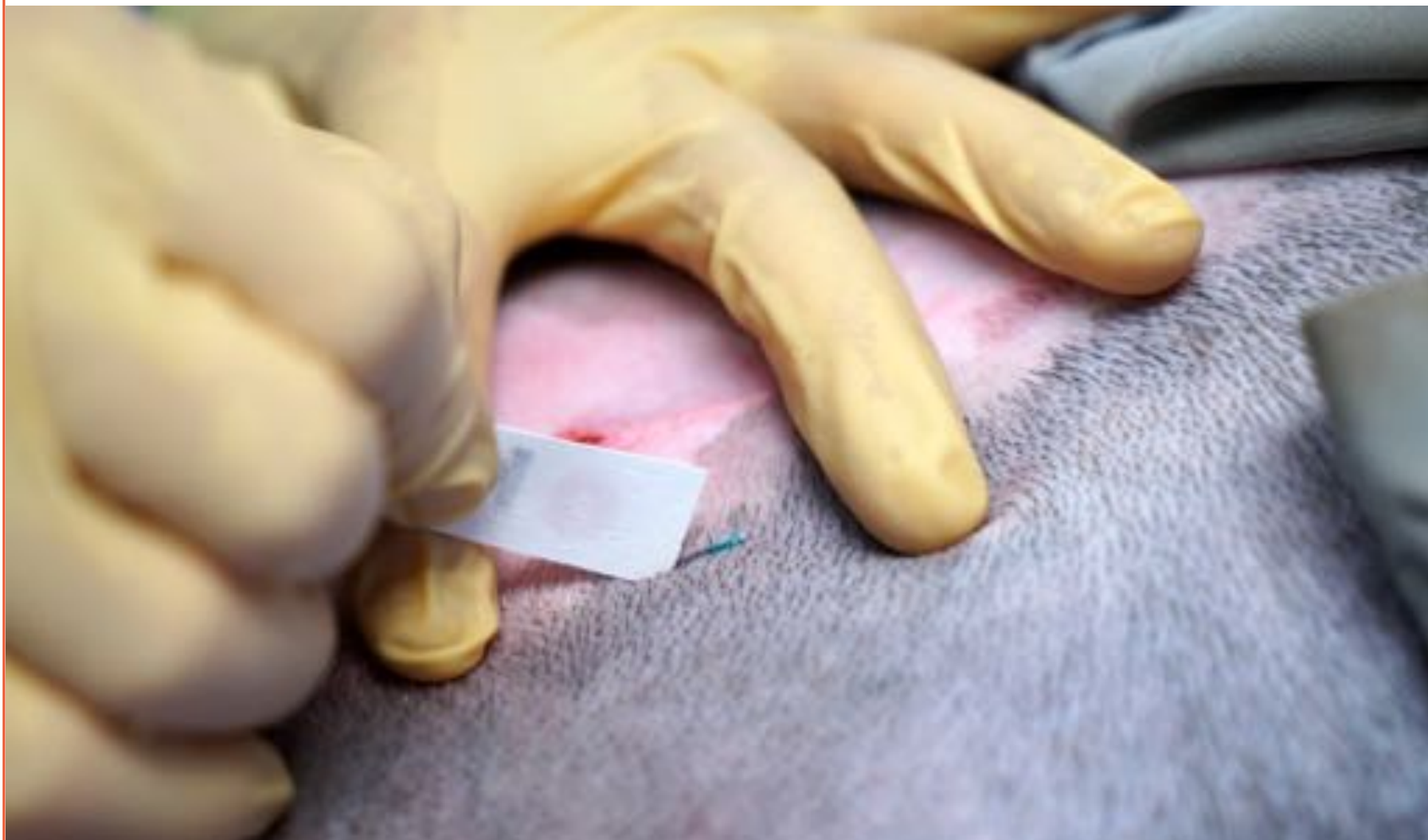Method of Scoring to Place Tattoo



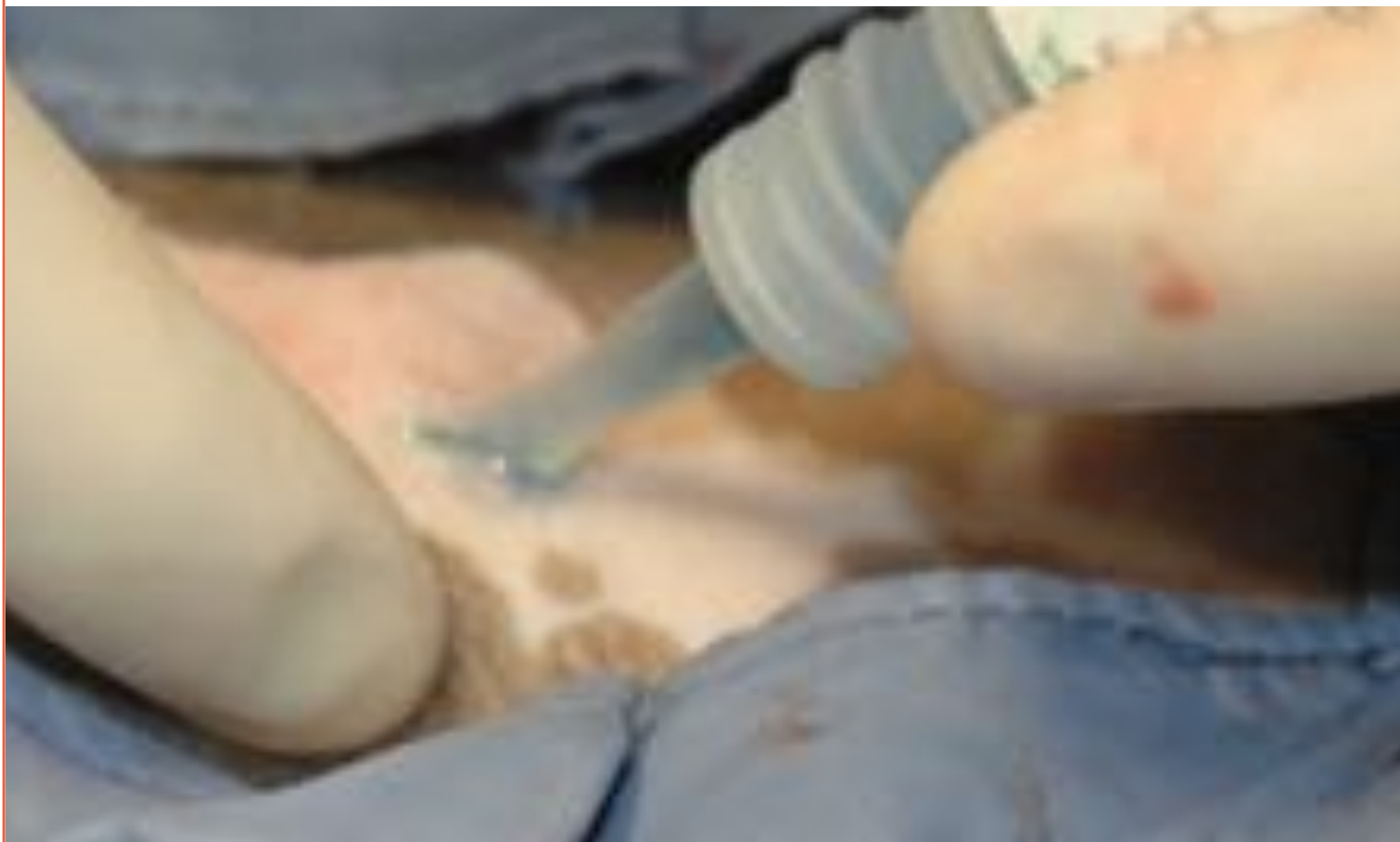
Tattooing



Tattooing



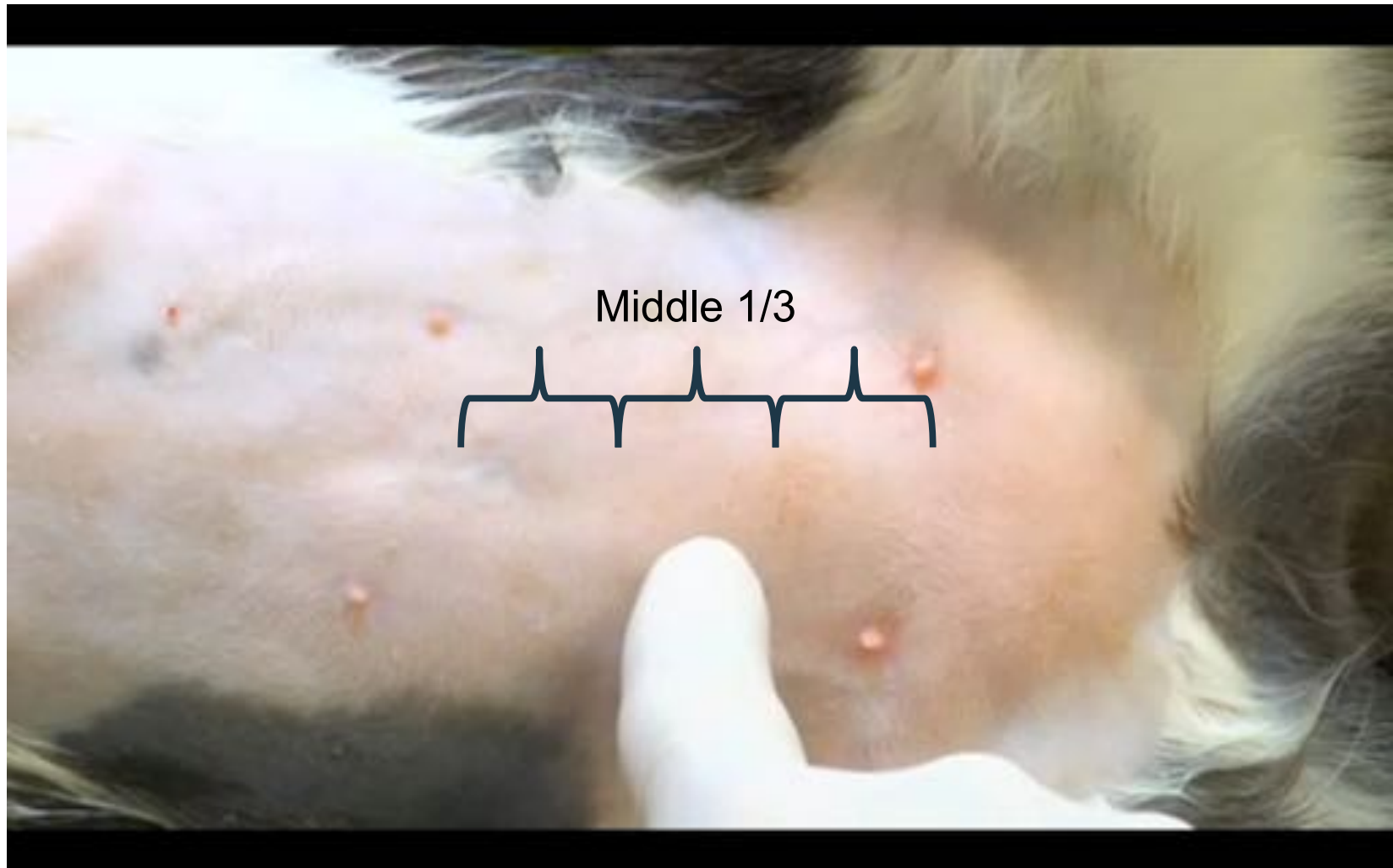
Tattooing: Glue



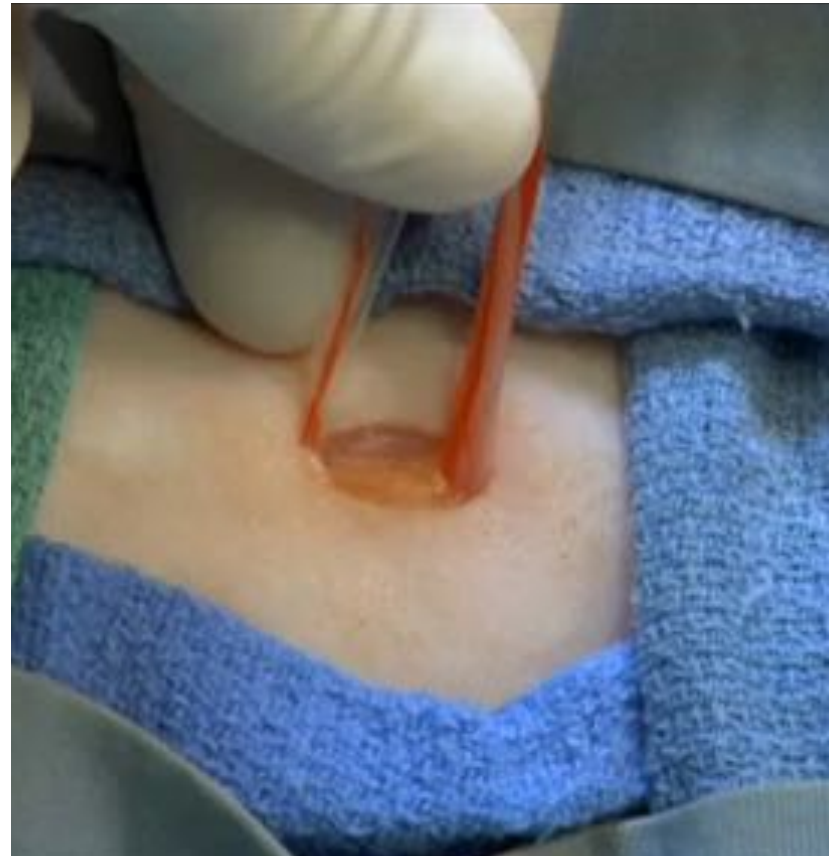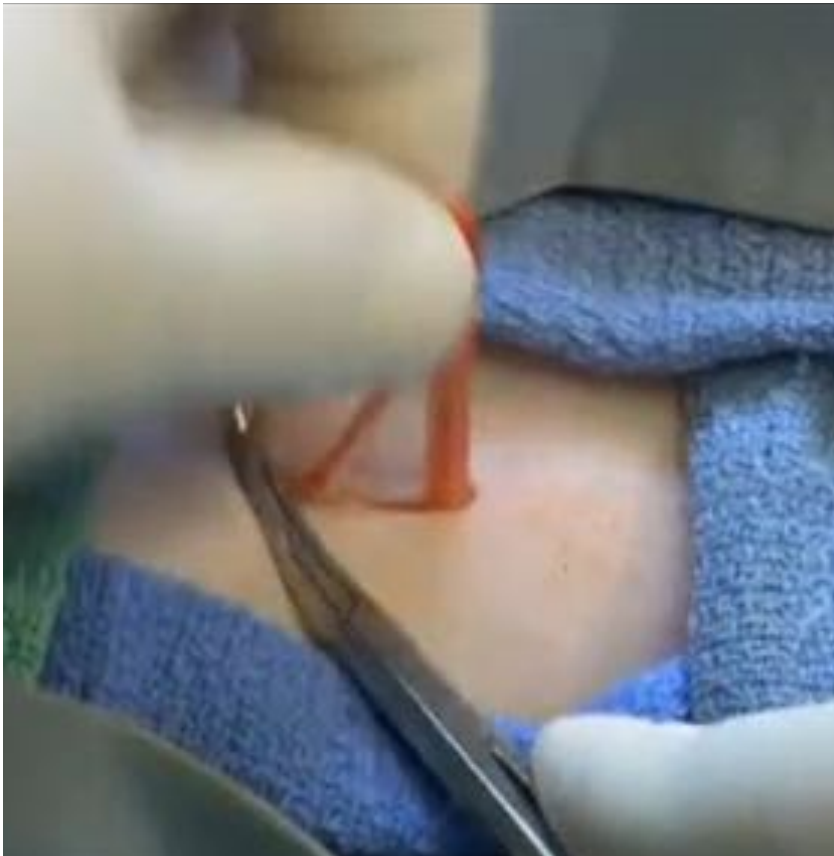Proficient Surgical Techniques – Female Cat



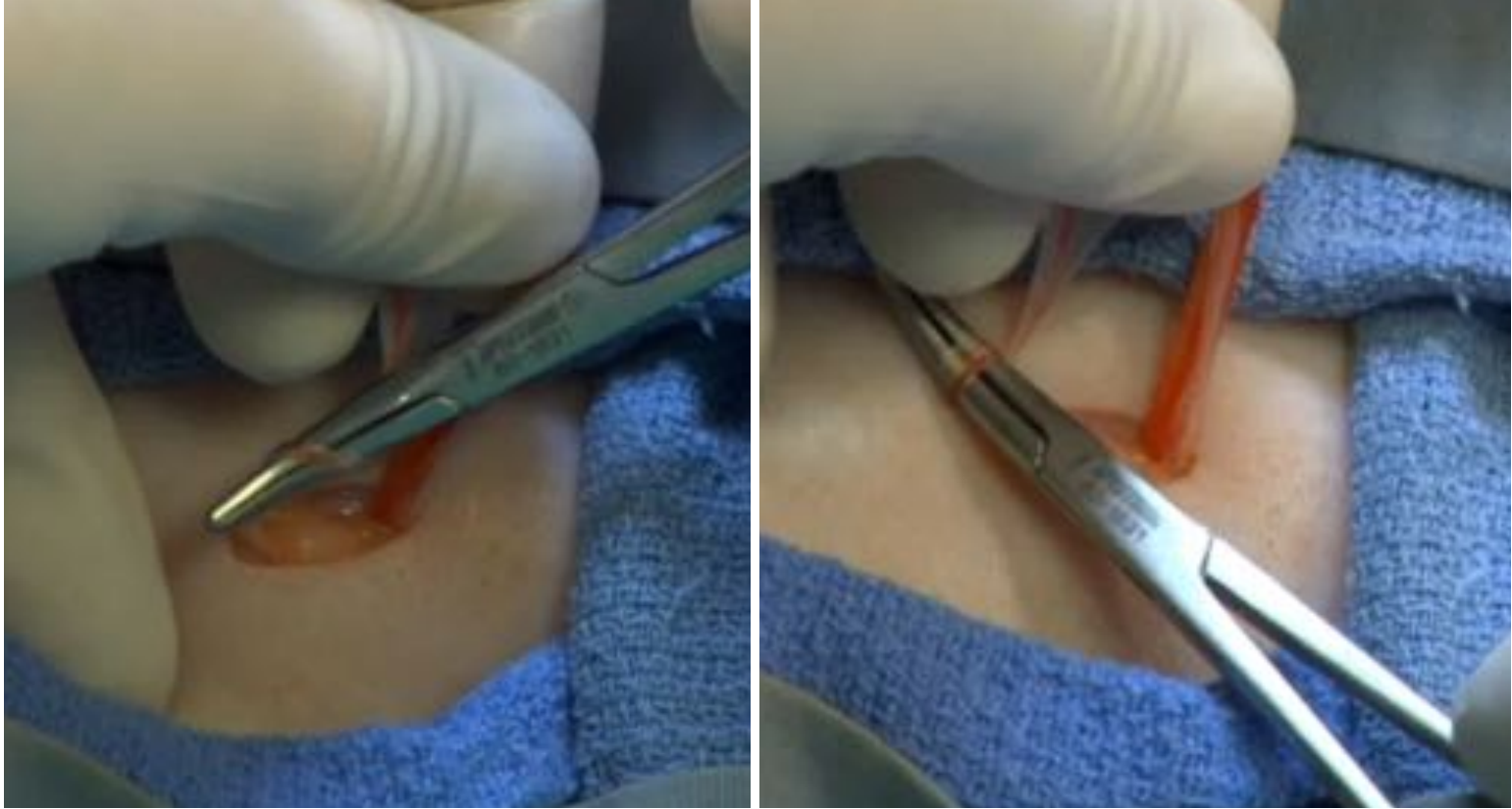Incision Placement – Cats, Kittens, Puppies



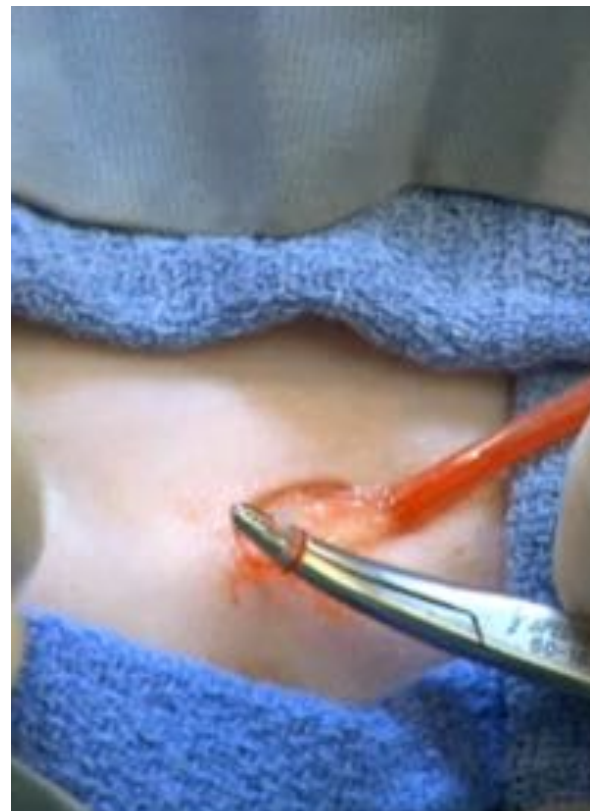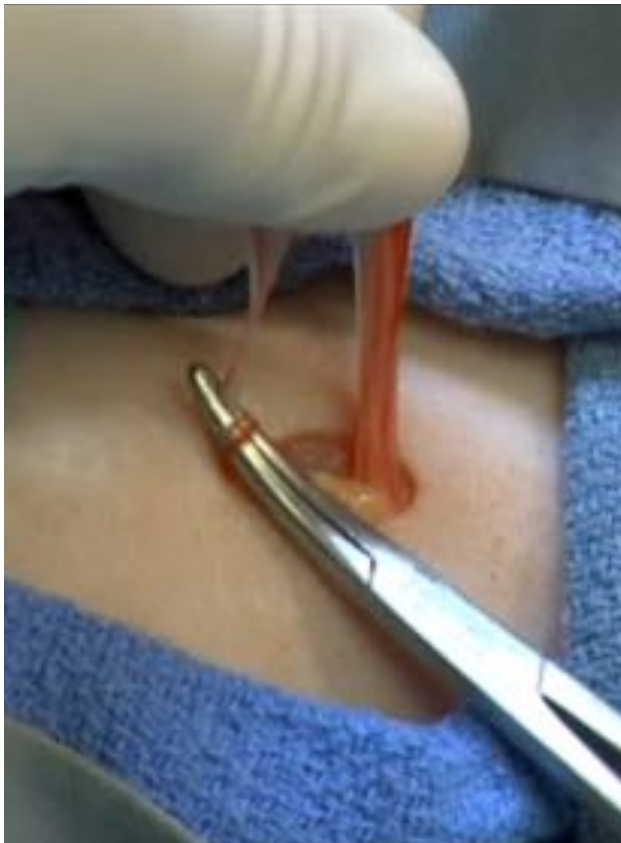Cats ONLY! Ovarian Pedicle Tie



Cats ONLY! Ovarian Pedicle Tie

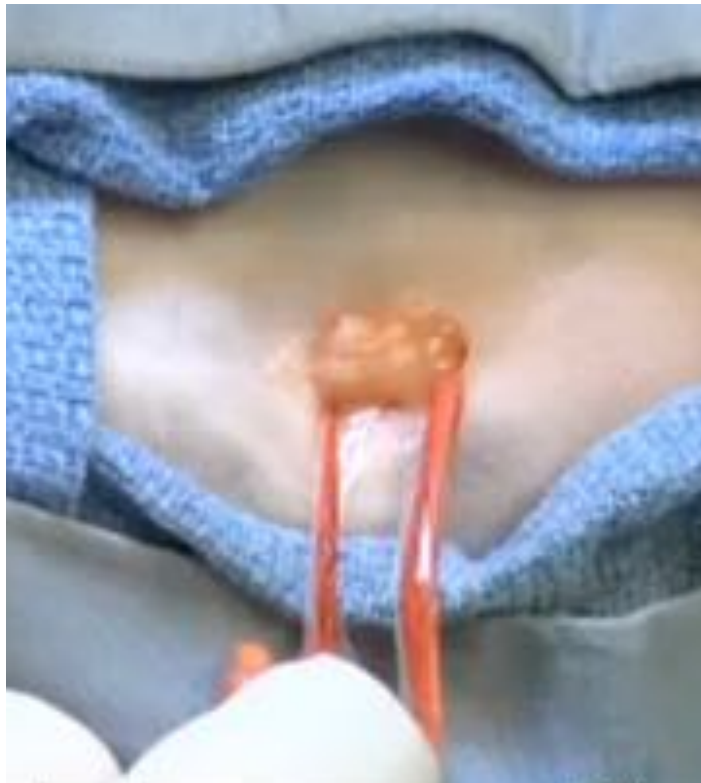

Cats ONLY! Ovarian Pedicle Tie

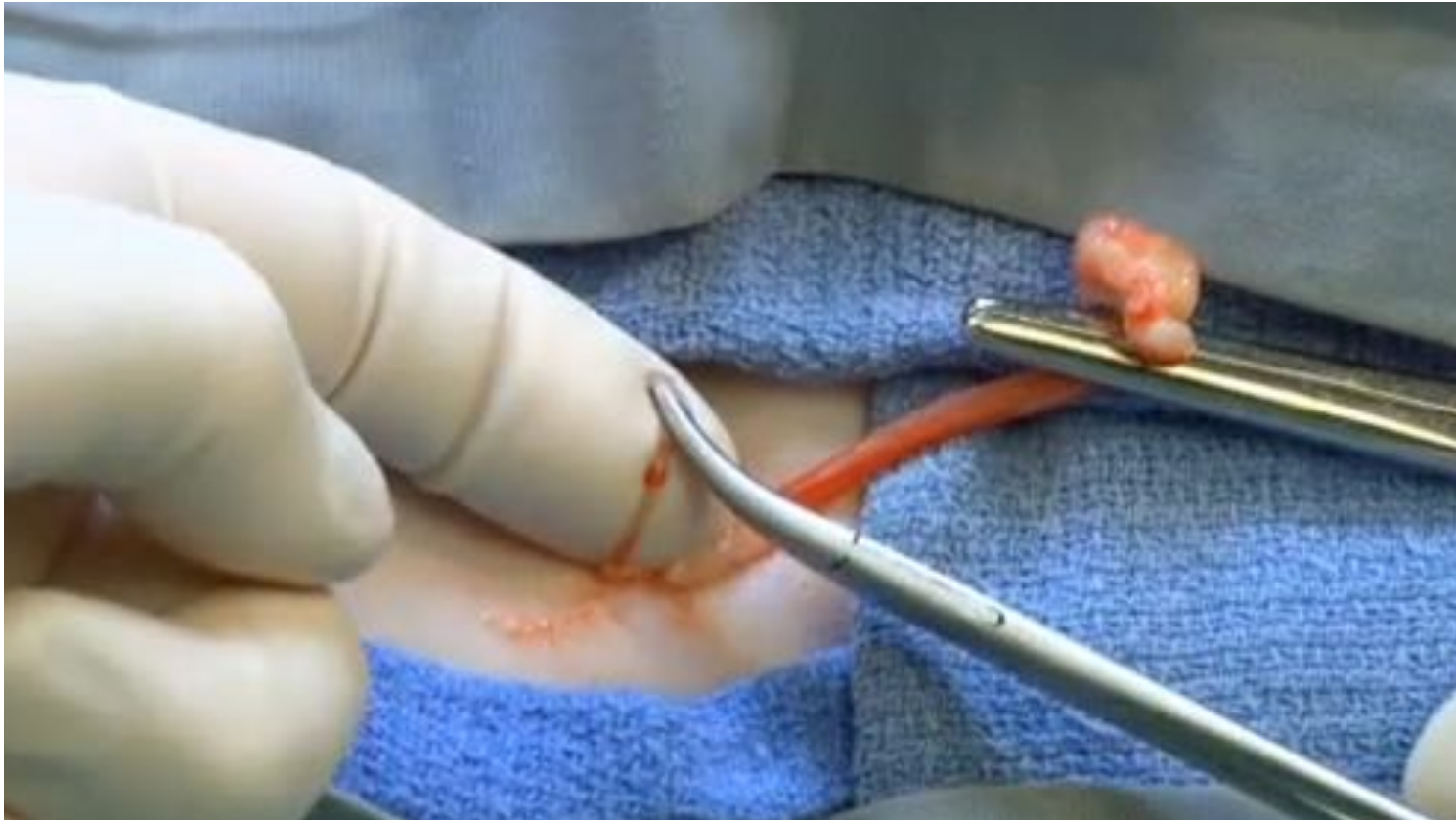

Cats ONLY! Ovarian Pedicle Tie


- Alternate method



Cats ONLY! Ovarian Pedicle Tie



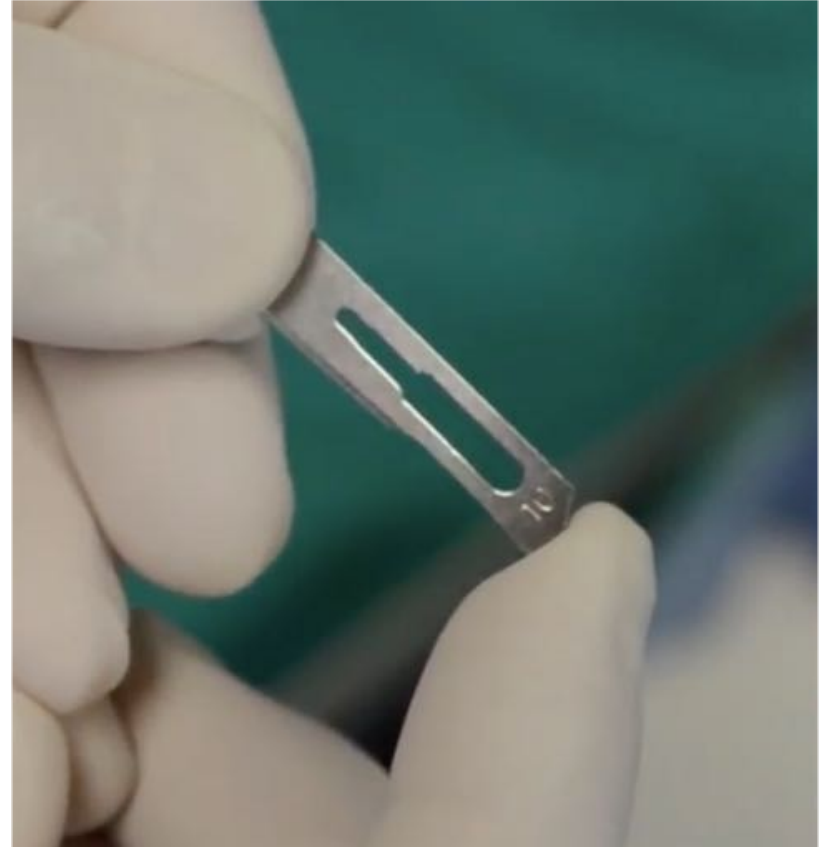
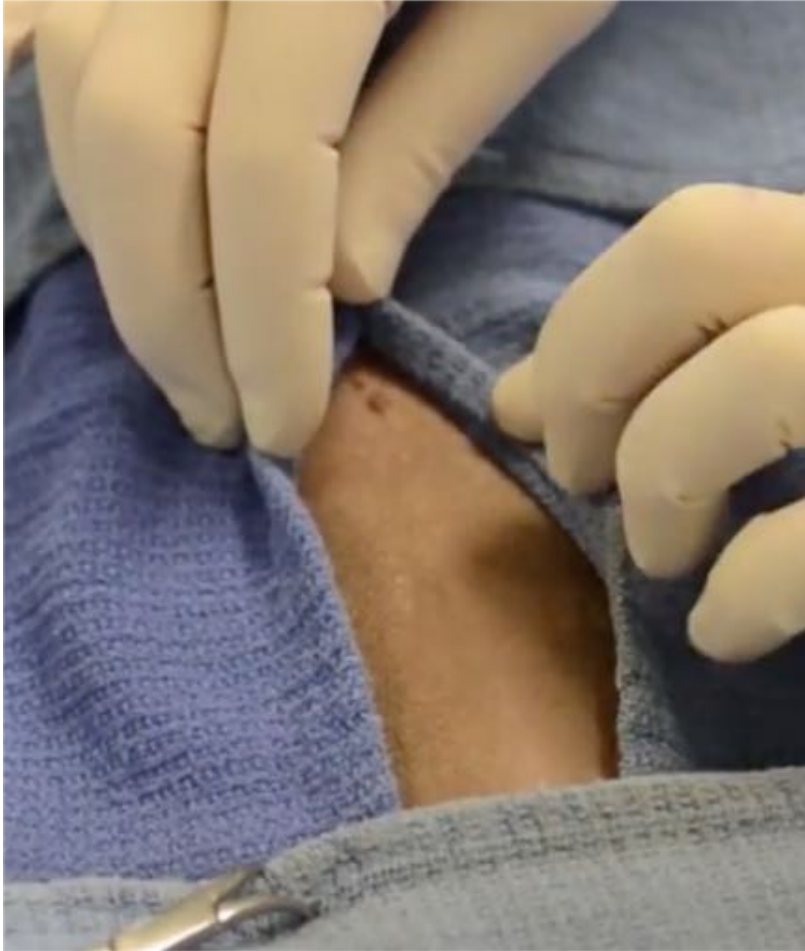Pedicle Tie: Video



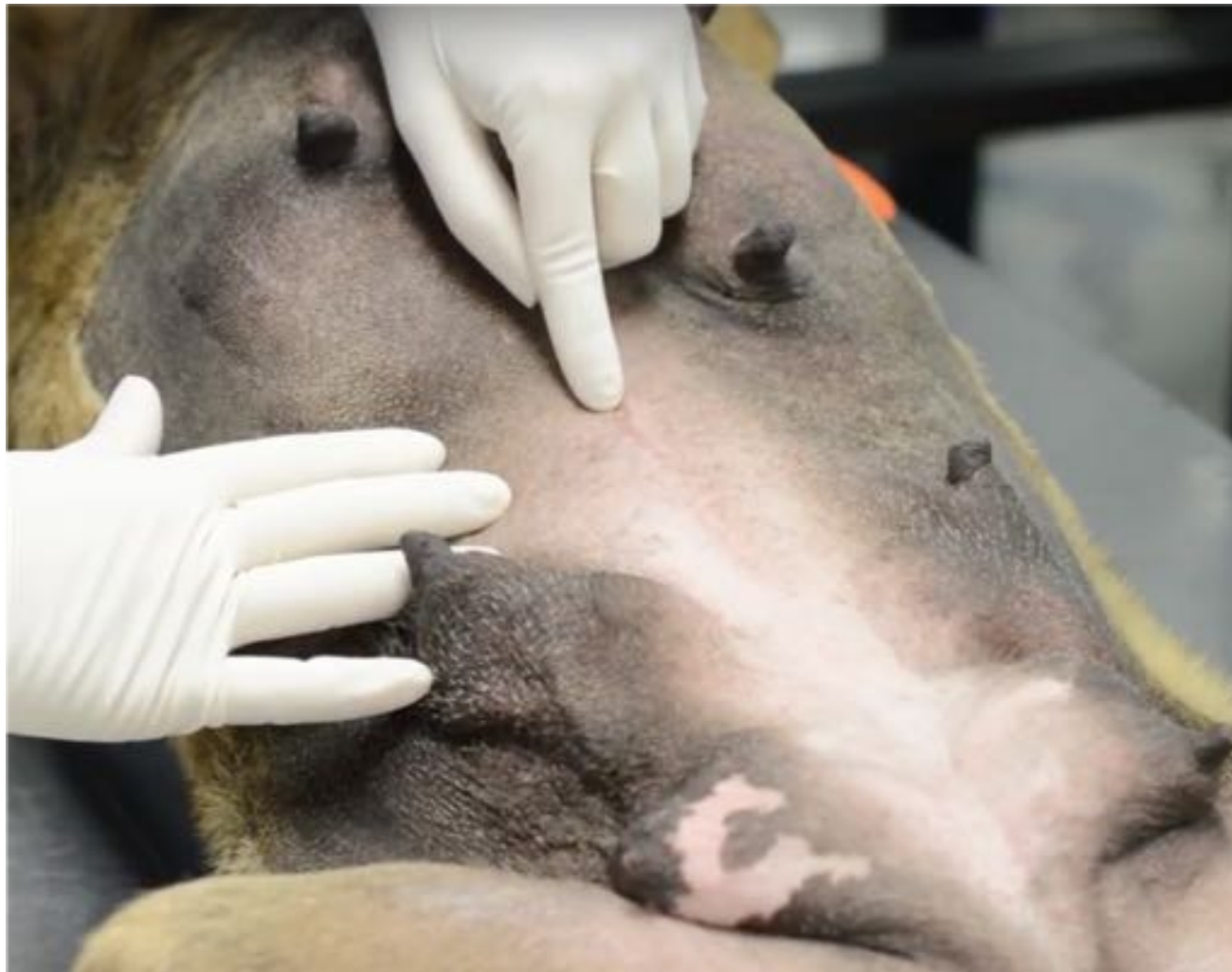Proficient Surgical Techniques – Female Dog



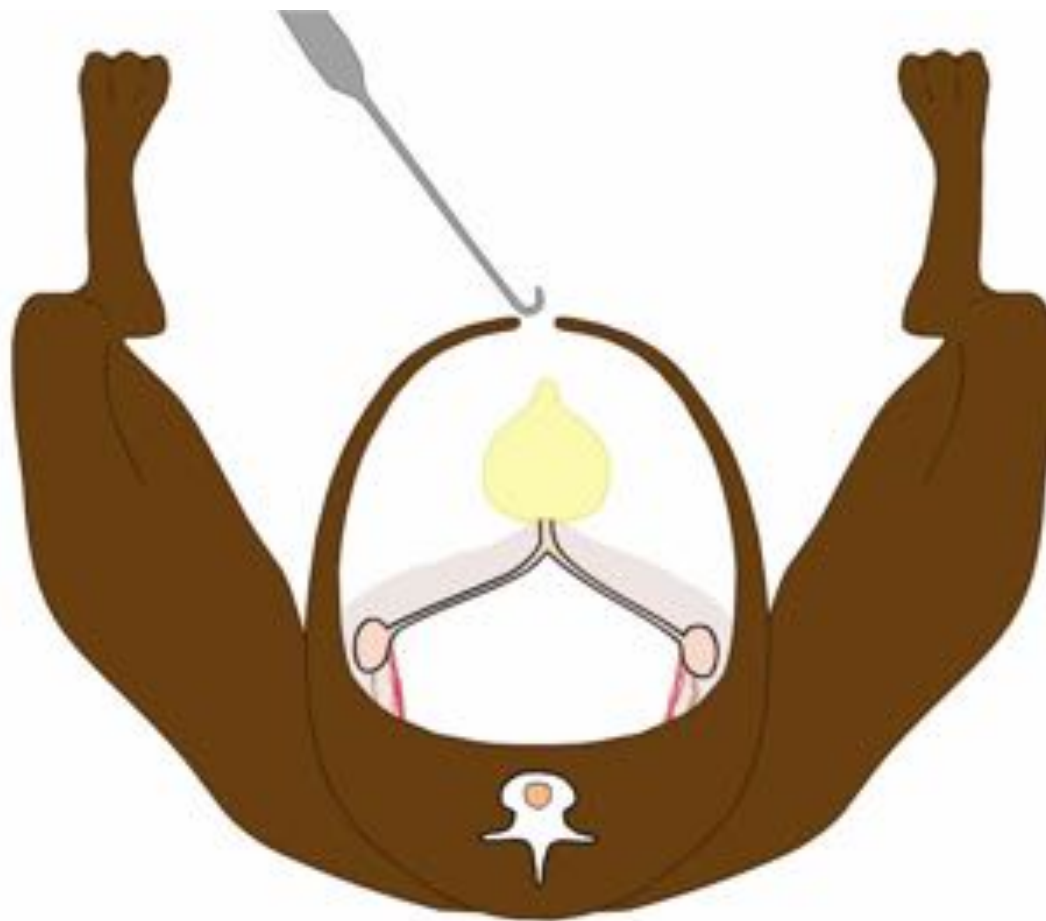
Incision Placement – Young FD (6-18 Mos)



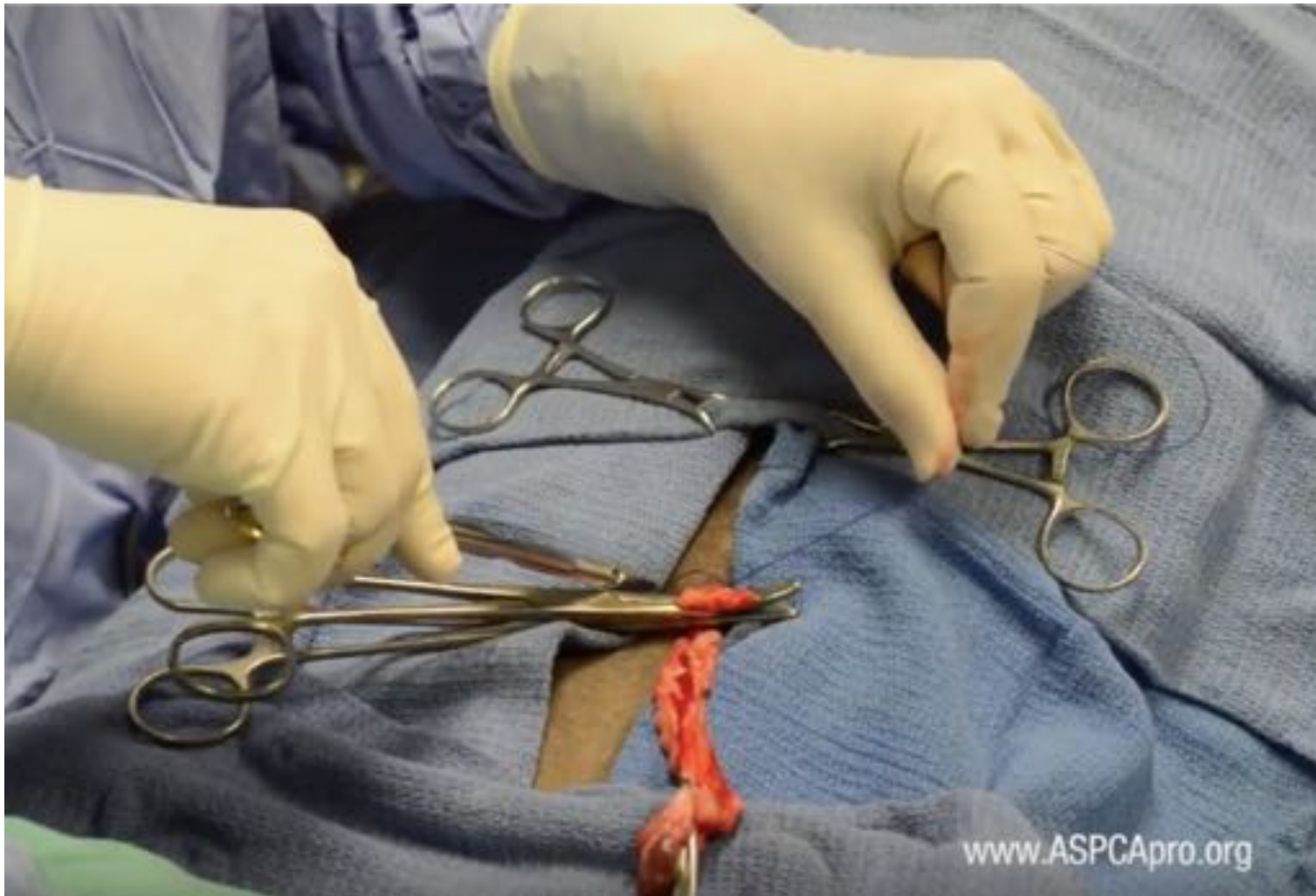Incision Placement – Mature Adult FD



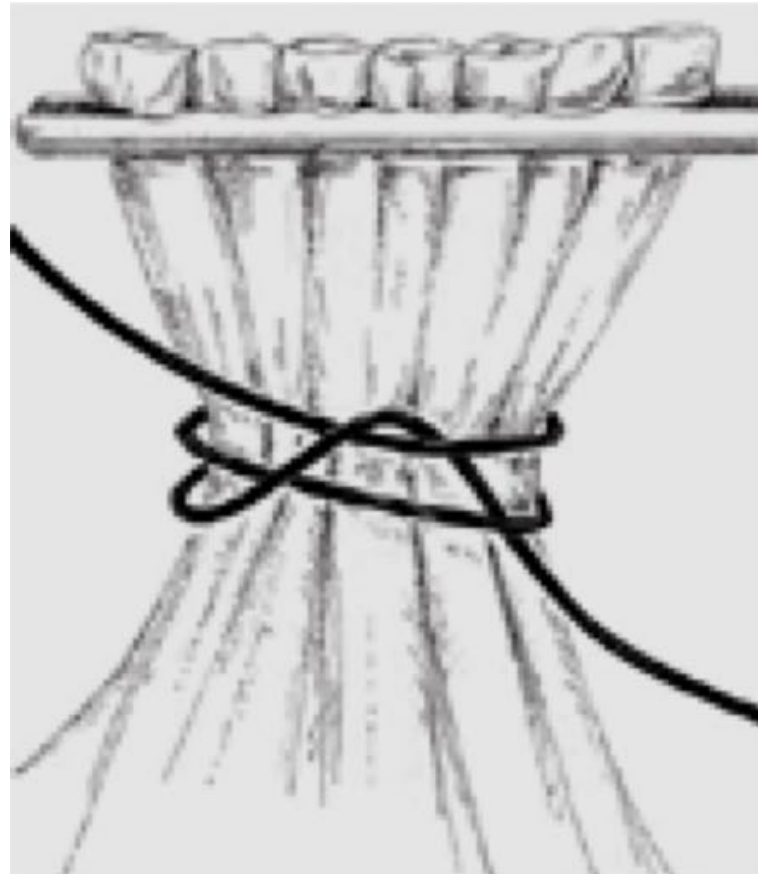
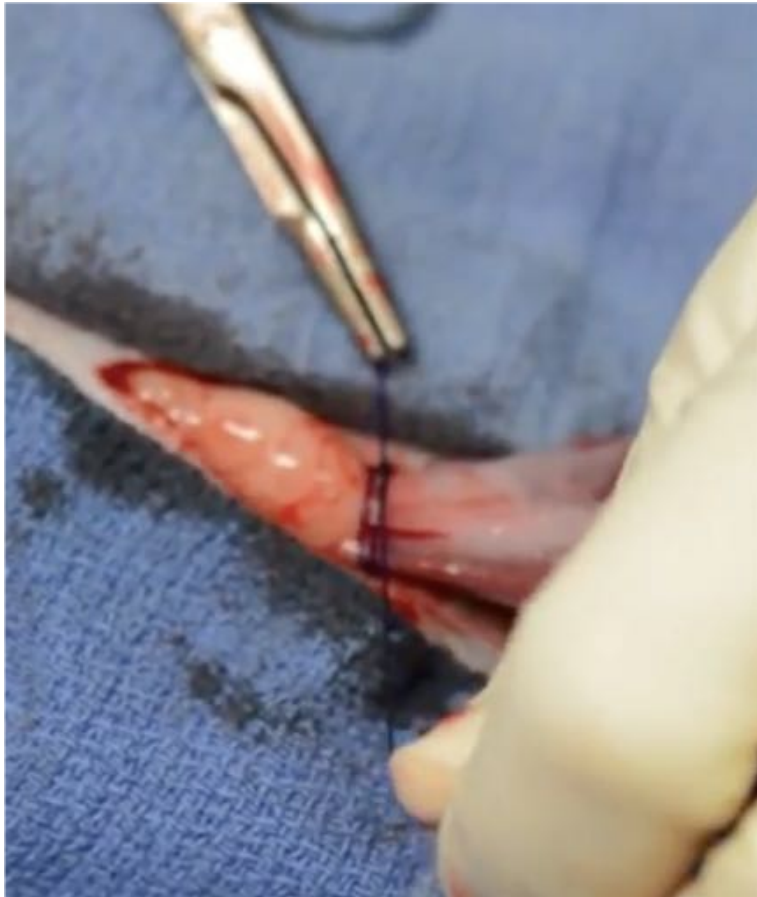
Spay Hook



Canine Ovarian Cutaway



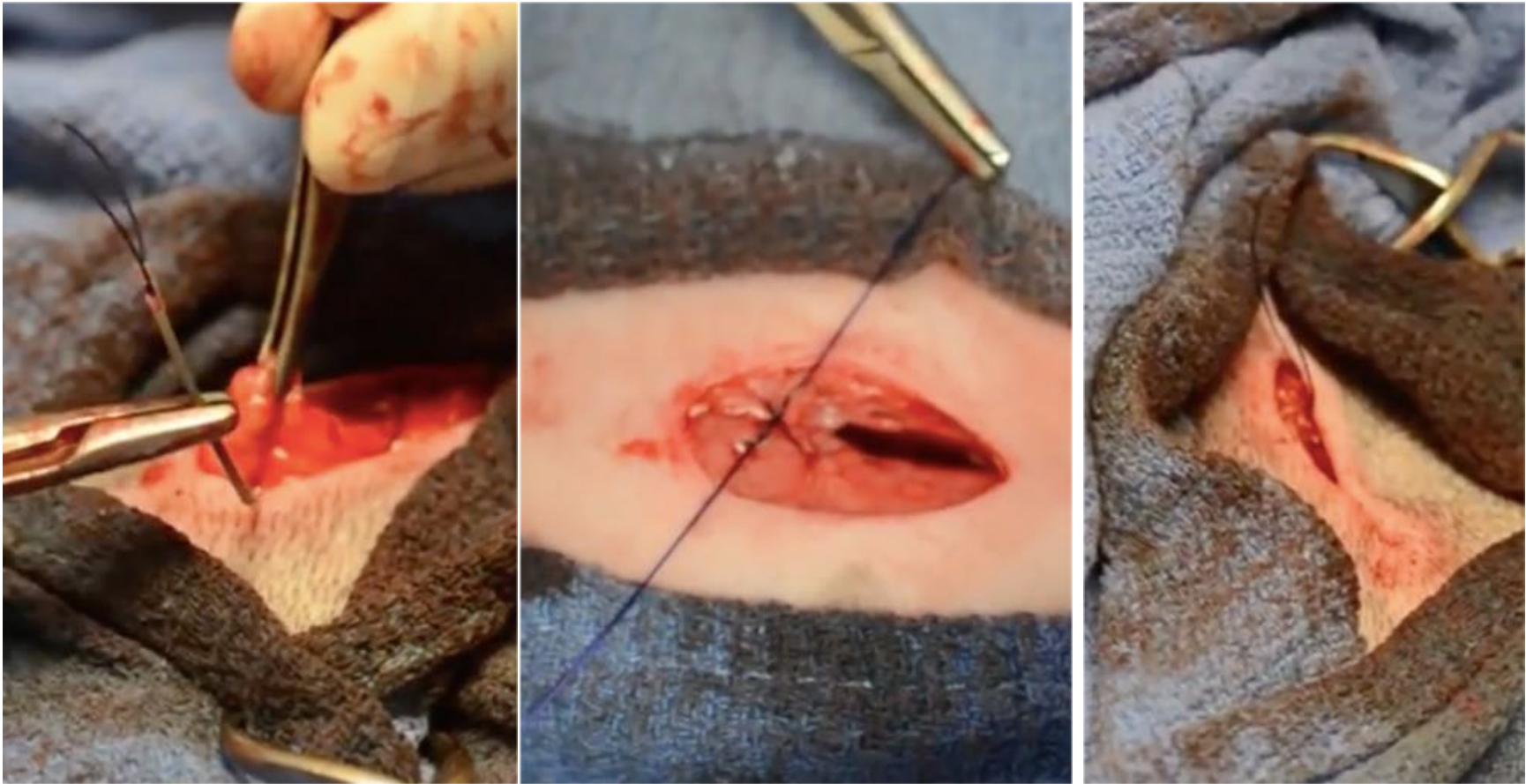Strangle Knot: Ovarian Pedicles & Uterine Body



Strangle Knot: Video



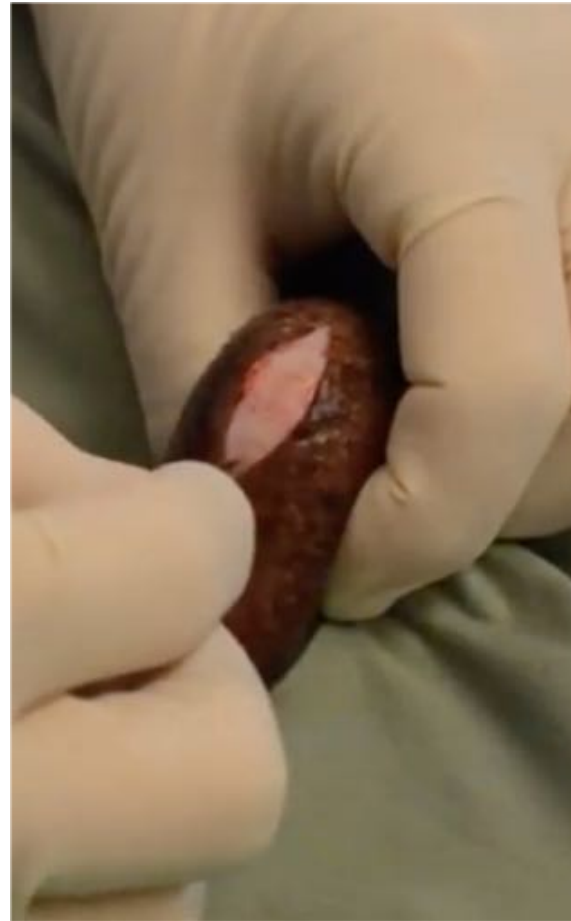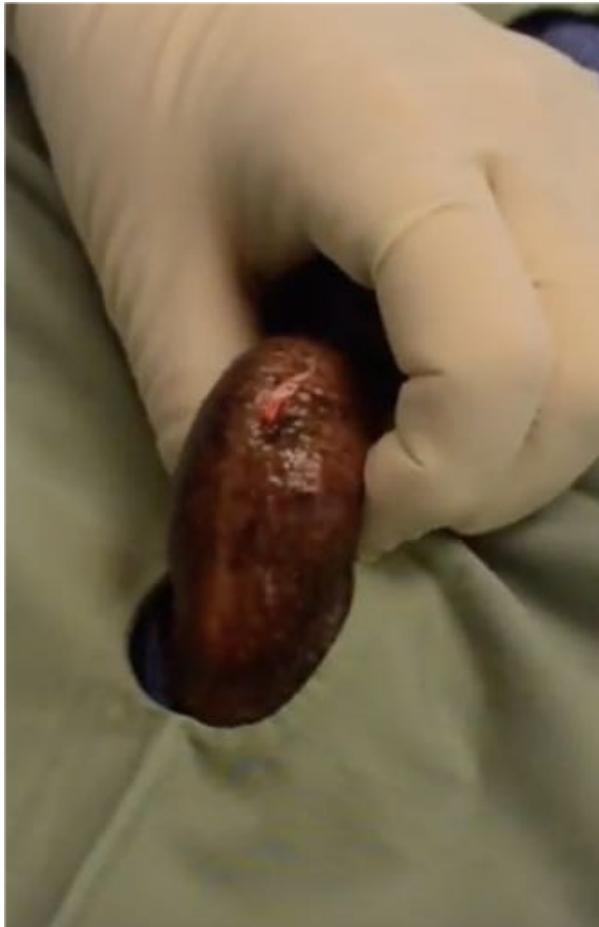Closure



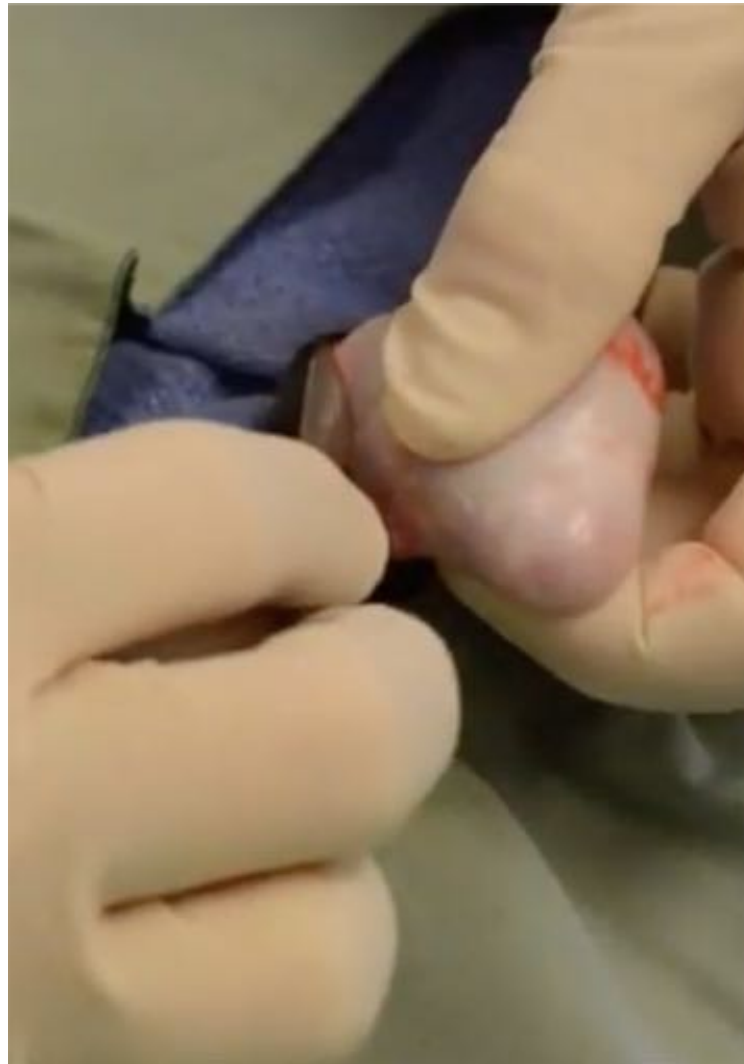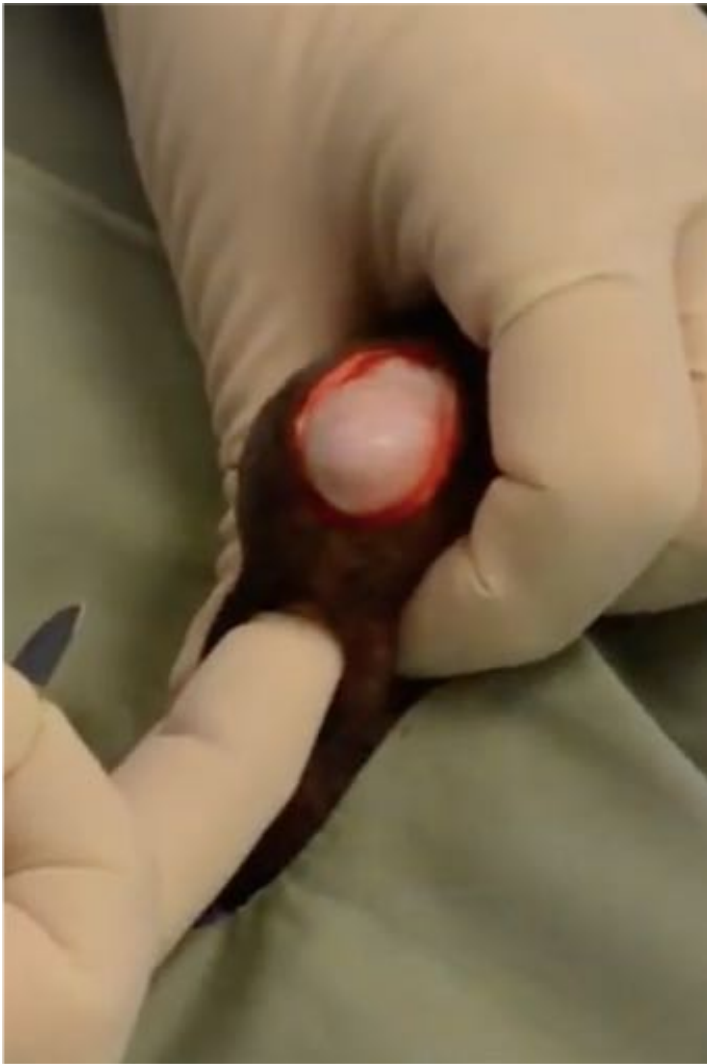Proficient Surgical Techniques: Adult Male Dog



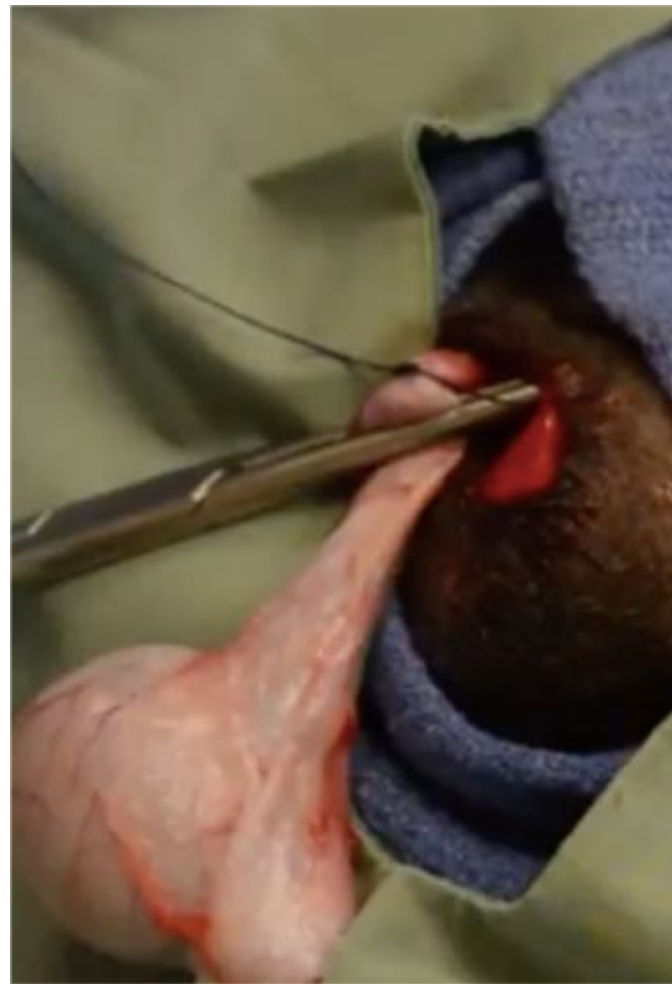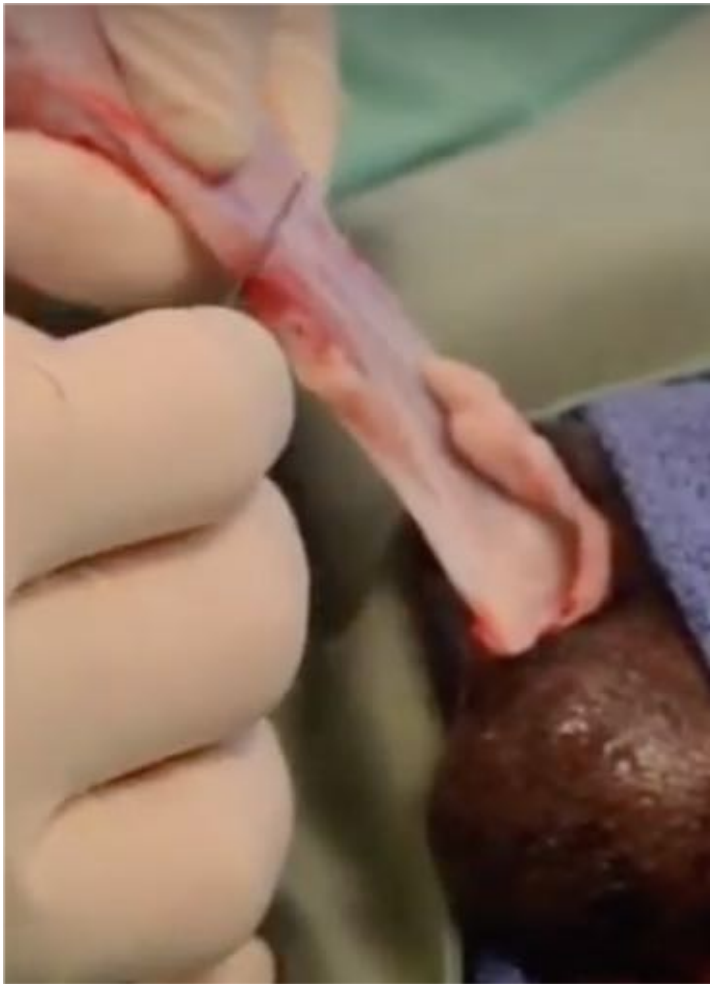Scrotal Approach in the Adult Dog



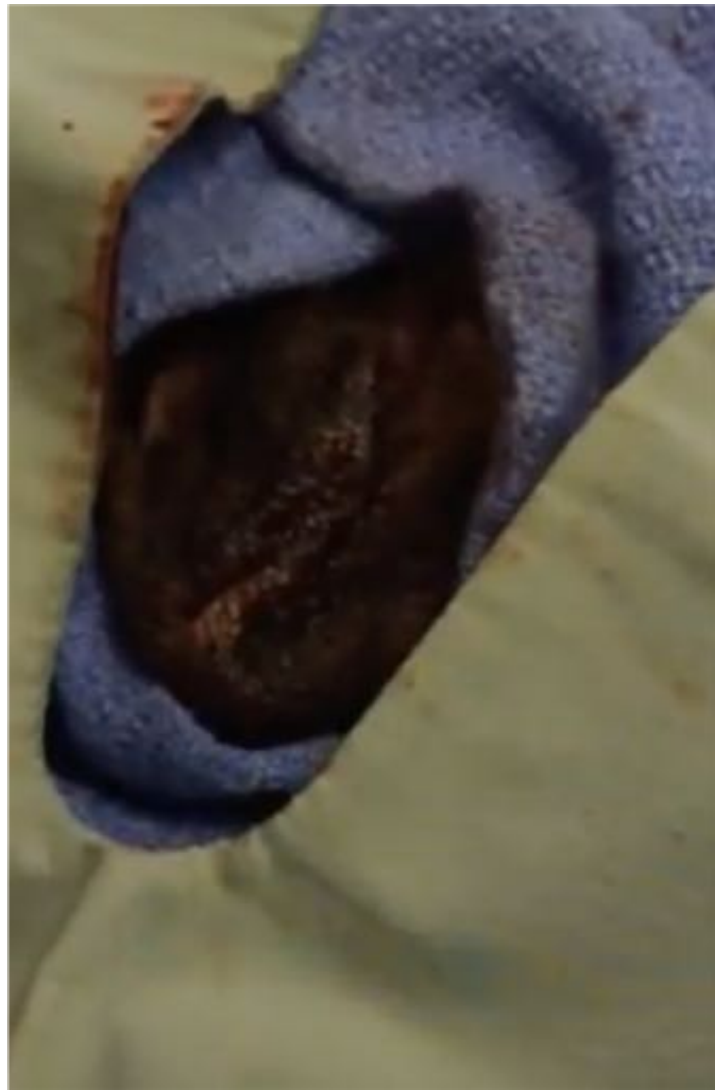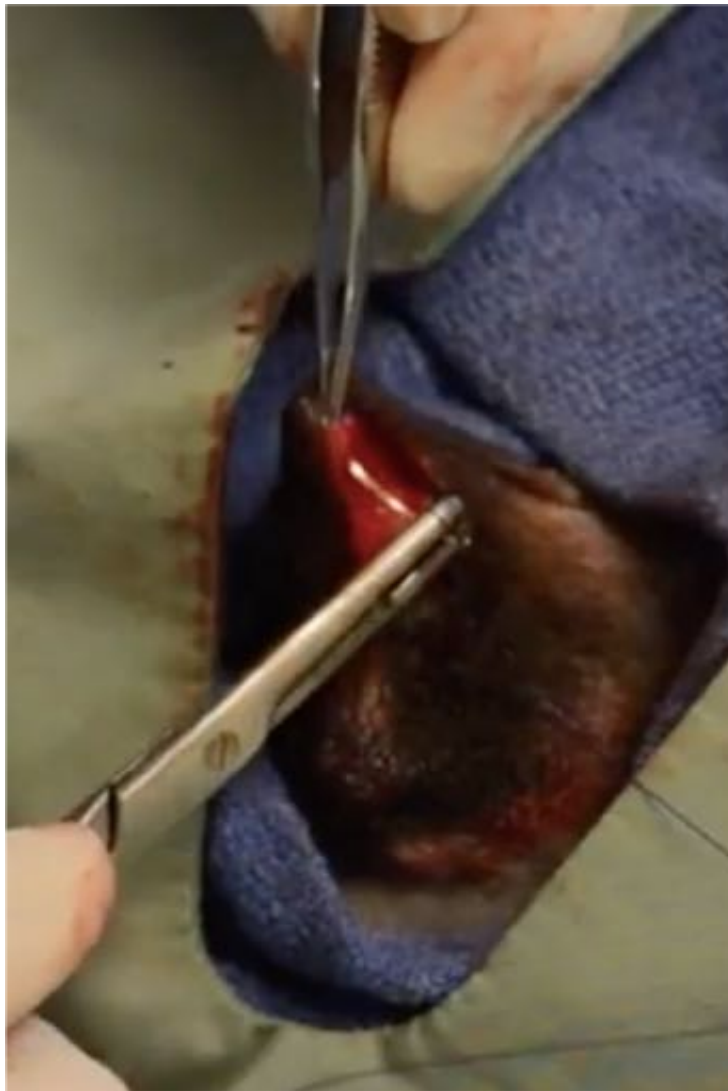Scrotal Approach in the Adult Dog



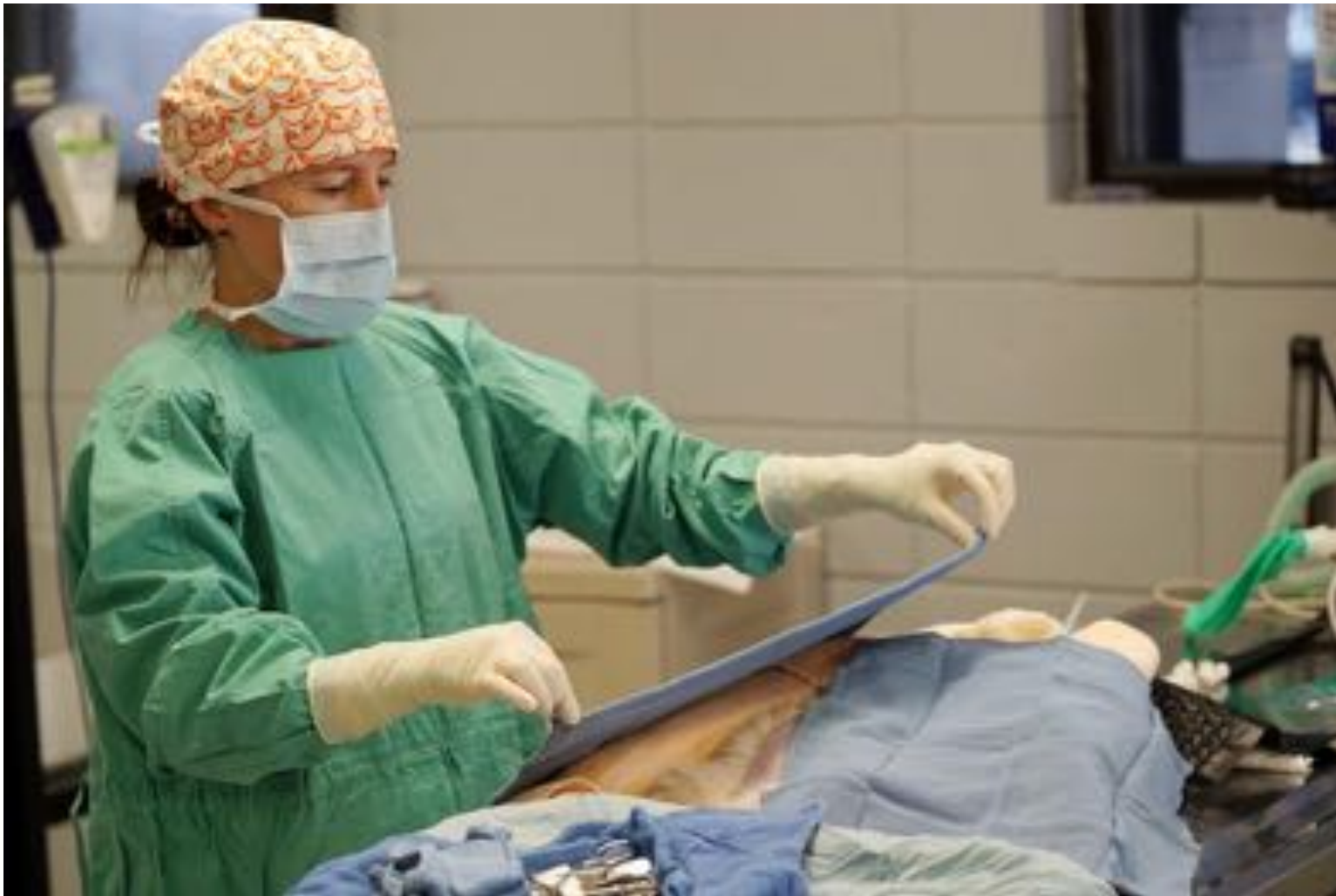Scrotal Approach in the Adult Dog



Scrotal Approach in the Adult Dog



Enhancement of Surgical Flow



Flow of Patients

- It is typical to follow a surgical order:
 - Pediatric patients
 - Dogs
 - Cats
 - Community cats



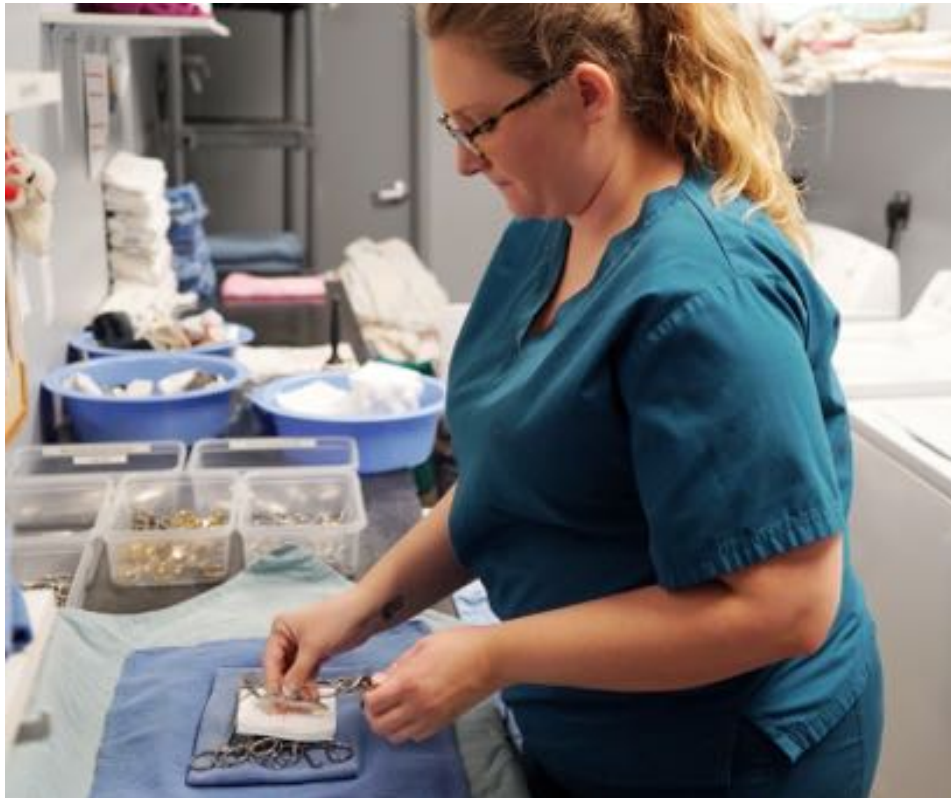Staff Predicting the Doctor



Streamlining: Patient Intake



Streamlining: Pack Preparation

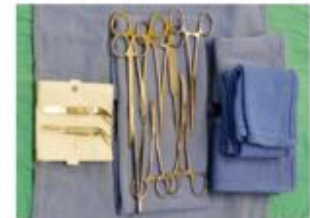

Surgical Pack Assembly - General Clinic

The contents of these packs may change per your surgeon's request/preferences.

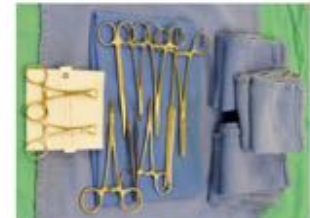Female Dog Pack (FD)

- 2 x ~~curved~~ mosquito (preferably 1 straight and 1 curved)
- 1 x spay hook
- 1 x ~~grile~~
- 1 x curved mosquito hemostat
- 1 x needle holder
- 1 x thumb ~~forcep~~
- 1 x pair of Metzenbaum scissors
- 2 x towel clamps
- 5 x surgical towels



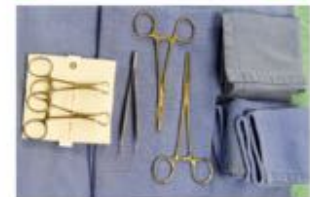Female Cat Pack (FC)

- 1 x ~~curved~~
- 1 x spay hook
- 1 x ~~grile~~
- 1 x straight mosquito hemostat
- 1 x curved mosquito hemostat
- 1 x thumb ~~forcep~~
- 1 x pair of Metzenbaum scissors
- 1 x needle holder
- 2 x towel clamps
- 5 x surgical towels



Male Dog Pack (MD)

- 1 x x-large ~~grile~~ or ~~curved~~
- 1 x needle holder
- 1 x thumb ~~forcep~~
- 2 x towel clamps
- 4 x surgical towels



All of the packs described above receive 5 pieces of gauze and a sterilization monitor strip.


Male Cat Pack (MC)

Assembled using a wrap and placing contents between two "bottom" towels:

- 8 x mosquito hemostats
- 8 x pieces of gauze
- 8 x blades (unopened)



Streamlining: Paperwork



3.5	0.2	0.30	0.24	0.28
4.0	0.2	0.30	0.27	0.32
4.5	0.2	0.30	0.30	0.35
5.0	0.5	0.30	0.3	0.4
5.5	0.5	0.30	0.3	0.4

Canine Drug Log

ham Leader: _____ Date: _____ Start: 1358556 Page # ①

ID #	Test	Dr.	Sx. Info.	Drug Info	ACE*	MORPHO*	KET*	BAR*	MEL*	Other	Chart
			Lot # Bottle # Amt. Used Waste	d1	0.50	0.30	0.30	0.40	0.20	0.30 lido	
			Lot # Bottle # Amt. Used Waste	d1	0.50	0.30	0.30	0.40	0.20		
			Lot # Bottle # Amt. Used Waste	d1	0.50	0.30	0.30	0.40	0.20		
			Lot # Bottle # Amt. Used Waste	d1	0.50	0.30	0.30	0.40	0.20		

Special Thanks to:

- Brenda Griffin, DVM, MS, DACVIM
- Julie Levy, Julie K. Levy, DVM, PhD, DACVIM, DABVP
(Shelter Medicine Practice)
- Philip A. Bushby, DVM, DACVS
- Mark Bohling, DVM, PhD, DACVS



ASPCA[®] Spay/Neuter Alliance